Journal of Medicinal and Chemical Sciences 6 (2023) 1180-1192

Journal of Medicinal and Chemical Sciences

Journal homepage: http://www.jmchemsci.com/

Original Article

Gray-Scale Ultrasonographic Features of Cervical Lymph Nodes in Patients with Newly Diagnosed Hodgkin and Non-Hodgkin Lymphoma

Ammar Jalil Sebahi*, Fawaz AL-Asawad

Department of Oral Diagnosis, College of Dentistry, University of Baghdad, Iraq

ARTICLE INFO

Article history

Receive: 2022-08-20
Received in revised: 2022-09-28
Accepted: 2022-11-07
Manuscript ID: JMCS-2210-1839
Checked for Plagiarism: **Yes**
Language Editor:
Dr. Fatimah Ramezani
Editor who approved publication:
Dr. Ali Delpisheh

DOI:10.26655/JMCHEMSCI.2023.5.24

KEYWORDS

Gray-scale Ultrasonograph
Cervical lymph nodes
Hodgkin's lymphoma
Non-Hodgkin's lymphoma
Lymphomatous lymph nodes
Oral physician
Oral and maxilla-facial health

ABSTRACT

The current study designated to evaluate Gray scale Ultrasound (US) parameters of the lymphomatous cervical lymph nodes (CLN) in Hodgkin's, Non Hodgkin's lymphoma (HL and NHL) patients, and normal CLN in normal control group, 92 CLN in 50 patients newly diagnosed with HL and NHL and 29 normal CLN in 25 healthy persons. (US) parameters including shape, echo pattern, fatty hilum, nodal border, cystic necrosis, coagulation necrosis and internal calcification, homogeneity, site of involvement, and status to the adjacent tissue of lymph nodes were noted. The shape (round), fatty hilum (absent), homogeneity (homogenous), lymph node status (matted), and echogenic pattern (reticular) presented with significant relationship (Si) that segregate NHL and HL in contrast to control group, cystic necrosis (present) presented with (Si) that segregate NHL in contrast to control groups with (Si) relation toward HL group, nodal border (regular) presented with (Si) in NHL in contrast to control group with no significant (NS) relationship with leftover groups, with (68.9%) in HL to be informative hyperechoic echogenic pattern presented with (Si) in control group in contrast to NHL, HL groups. The other parameters such as site of involvement, coagulation necrosis, internal calcification, and hypoechoic and isoechoic echogenic pattern presented with (NS) relation among studied groups. Gray-scale US parameters outcome round shape, absent Hilum, homogenous architecture, lymph node status (matted), and reticular echo pattern were a strong clinical diagnostic features in lymphomatous CLN that predict occurrence of NHL, HL, with more presented matted lymph nodes in NHL than HL group. Cystic necrosis (present) was strong clinical indicator for the NHL occurrence prediction.

GRAPHICAL ABSTRACT

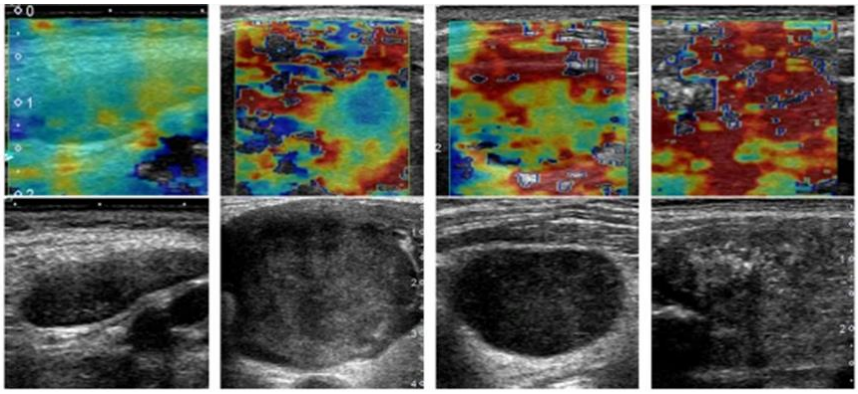

* Corresponding author: Ammar jalil sebahi
✉ E-mail: Email: Sebahiammar708@gmail.com

Introduction

The lymphatic system is a component of the immune system, integral to the peripheral vascular system, and metabolic system, it is made up of an extensive network of lymphatic capillaries, lymph nodes, lymphatic organs, and lymphoid tissues, it drains the extra-vasated fluid from blood capillaries in the tissue which supply nourishment to the tissue, and then this fluid (lymph fluid) collects damaged cells, bacteria, viruses, and cancer cells to be filtered in the lymph nodes [1].

The lymphatic system serves as the principal location for lymphocytes (B, T cells) related to the adaptive immunity and natural killer cells (NK) related to innate immunity within the lymph nodes, which play important roles in the immune system of the body [2].

The lymph node has a kidney-like shape, and lymph fluid enters it through the afferent lymphatic vessels, and after cleaning and filtering it comes out of the gland through one or two efferent lymphatic vessels to return back to the circulatory system, there are about 800 lymph nodes in the human body, 300 in the neck which termed cervical lymph nodes (CLN) [3, 4].

Lymphoma is a cancer of the lymphatic system, it begins in B, T cells, and NK cells, which are a type of white blood cell, that fight diseases in the body, and play an essential role in the body's immune mechanism, it can spill over into blood (leukemic phase) and can infiltrate to different tissues and organs throughout the body, the main subdivisions are Hodgkin lymphoma (HL) and Non-Hodgkin lymphoma (NHL), based on the presence of Reed- Sternberg (RS) cells in HL [5].

Cervical lymph nodes (CLN) are frequently involved in a number of disease conditions, the most commonly seen causes of cervical lymphadenopathy are tuberculosis, distant metastasis, and lymphoma in which it is the most common sites of involvement in HL and NHL patients [6], and lymphoma may be presented as the only cervical lymphadenopathy, the oral physicians have to gate keep the oral and maxilla-facial health and increase the awareness toward cervical lymphadenopathy. Furthermore, there is a responsibility to detect the early manifestations of various systemic diseases is crucial in prognostication and further treatment planning and to provide the appropriate patient care [7].

Ultrasonography (US) especially B-mode ultrasound (gray-scale) which commonly used to examine CLN can be used as the first-line imaging devise without ionizing radiation in the diagnostic evaluation of cervical lymphadenopathy, due to its ease, non-invasiveness, reproducibility, and cost-effectiveness [8].

When several sonographic parameters are taken into account, high resolution conventional ultrasound provides a high sensitivity, specificity, and accuracy in discriminating benign and malignant cervical lymphadenopathy *serap et al* [9], also Abdelgawad *et al*; 2020 [8] mentioned in their study that gray scale sonographic parameters presented with sensitivity of 94% and accuracy of 71.9% for assessment various causes of lymphoadenopathy.

Early cervical lymphadenopathy diagnosis and the early treatment plane leads to the good prognosis as many types of lymphoma, especially indolent NHL present with waxing and waning lymphadenopathy for many years, as mentioned by Sapkota and Shaikh (2022) in their study to evaluate sign and symptoms of NHL [10].

The objective of the study was to Evaluate Gray-scale US parameters of the involved lymphomatous CLN in (HL), (NHL) patients, and normal CLN in control group, to determine the main Gray-scale US parameters that predict HL and NHL occurrence.

Materials and Methods

This a cross-sectional study, approved by the Ethical Committee of Collage of Dentistry, Baghdad University (Project No. 632722) and conducted at Hematology Center in Baghdad Teaching Hospital, Baghdad Medical City, AlKaadimeya Medical City and Radiology Department, Al-Yarmook Teaching Hospital, all of centers in Baghdad, Iraq. The study population included 25 patients (11 males and 14 females) with HL with 45 lymphomatous CLN and 25 patients (15 males and 10 females) with NHL with 47 lymphomatous CLN, both diagnosed

according to histopathology and immunephenotyping, both groups associated with cervical lymphadenopathy, those patients were examined pre chemo and radiotherapy, Inclusion criteria for lymphomatous CLN were (the absence of fatty hilum, the minimum transverse diameter of 10 mm or larger, round shape, echo reticulation, and hypoechoic echogenicity) and 29 normal CLN 25 (13 males and 12 females) healthy control group with no history of neck surgery, glandular fever, chronic tonsillitis, tuberculosis, head and neck malignancy, or lymphomas, inclusion criteria for normal lymph nodes (oval shape, hypoechoic, with fatty hilum). Age and sex match with patients groups from 15- >60 years old.

Gray-scale US examination was done by radiologists using Voluson Ultrasound Machine; the ultrasound machine was with multi-frequency (7-14 MHz) and GE 11L-D Linear array probe. Scanning patients was performed while the patient was in the supine position, with the neck of the patient hyperextended with a pad or pillow under the shoulders to provide the optimum exposure of the neck. The Gray-scale US parameters including lymphnode shape (Lymph nodes with a Short / Long axis ratio (S/L) < 0.5 mm were accepted as oval nodes, whereas those with a S/L 0.5 mm or more were accepted as round nodes). The echogenic pattern of the lymph node was classified as hypo, hyperechoic, Isoechoic, and reticular compared with the surrounding musculature, reticular pattern was described as a micro-nodular echo mould. The fatty hilum was defined as presence (vascular) or absence (avascular). The border of the lymph node was classified as regular or irregular according to the boundary between the lymph nodes and the surrounding soft tissues. The internal structure of the lymph node (present/absent) was evaluated for the presence of calcification, cystic (liquefaction necrosis), and coagulation necrosis, coagulation necrosis the later usually echogenic, irregularly demarcated, and is not continuous with the surrounding fat. Lymph node status to the surrounding tissue described as matted or discrete and site of involvement according to Hajek's classification: (1) submental, (2) submandibular, (3) parotid, (4) upper cervical, above the hyoid bone and along the common carotid artery (CCA) and internal jugular vein (IJV), (5) middle cervical, between the hyoid bone and the cricoid cartilage, along the (CCA), and (IJV), (6) lower cervical, below the cricoid cartilage, and along the (CCA) and (IJV), (7) supraclavicular fossa and (8) posterior triangle (Figure 1). Finally, the homogeneity of lymphnode architecture was maintained with the (homogenous/heterogeneous) outcome.

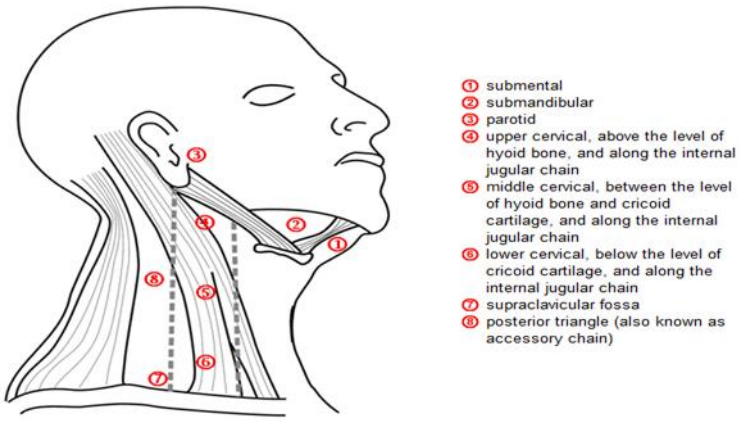

Figure 1: Hajek classification of cervical lymph nodes

Objectives and aims of the study

The present study designated to evaluate the gray-scale US parameters of the involved lymphomatous CLN in (HL), (NHL) patients, and normal CLN in control group, to make comparison between US parameters outcomes of the involved lymphomatous CLN of (HL) and (NHL) patients and in contrast to the normal CLN

in control group (healthy patients). To determine the main Gray-scale US features of HL and NHL groups, in contrast to that in control group, to estimate the US parameters that predict an occurrence of HL and NHL to increase the awareness of oral physician and dental practitioners toward the early diagnosis of patients with cervical lymphadenopathy.

Statistical analysis

The comparison of qualitative variables was made through the contingency coefficients (C.C.) test for the cause's correlation ship of the contingency tables and one sample Chi-square test. This test compares the observed and expected frequencies in each category to test either that all categories contain the same proportion of values or that each category contains a user-specified proportion of values. Fisher's exact test: Crosstabs' statistics and measures of association are computed for two-way tables only. The One-way ANOVA procedure produces a one-way analysis of variance for a quantitative dependent variable by a single factor (independent) variable with statistical package (SPSS) ver. (22.0).

Results and Discussion

Table 1 demonstrated the distribution of demographical characteristics variables (DCVs), with respect to gender studied groups had (NS) different at P=0.157 among the studied groups (HL, NHL, and control groups). But within HL, NHL groups, there was an increase in female patients in HL group, while male patients were the highest registered in NHL group, age group's distribution of the studied groups had a (Si) different at P=0.002 among the studied groups with means and deviations of the studied groups (control, NHL, and HL) were recorded (37.69 ± 12.67), (47.92 ± 14.91), and (28.84 ± 11.05) years old, respectively.

The results in Table 2 showed that control group has recorded "Oval" lymph node shape (75.9%), while most cases of NHL, HL groups has recorded "Round" lymph node shape (Figure 2) (70.2% and 77.8%), respectively, the results revealed (Si) relation with lymph node shape bet NHL, HL groups, and control group at P=0.000. On the other hand, regarding site involvement, the distribution of CLN site of involvement among studied groups (NHL, HL, and control group) shows (NS) relation at P= 0.359, which indicates the similarity of the selection of lymph nodes in different sites on all the studied groups.

Table 1: Distribution of DCVs for the studied NHL, HL, and control group with testing significant

DCV.	Diagnosis	Control		NHL		HL		C.S. (*) P-value
	Classes	No.	%	No.	%	No.	%	
Gender	Male	13	52	15	60	11	44	CC= 0.196 P=0.157 (NS)
	Female	12	48	10	40	14	56	
	Total	25	100	25	100	25	100	
Age Groups Yrs.	< 20	1	4	1	4	7	28	CC= 0.522 P=0.002 Si
	20 _	7	28	2	8	9	36	
	30 _	6	24	4	16	3	12	
	40 _	5	20	6	24	5	20	
	50 _	4	16	7	28	1	4	
	60 _ 70	2	8	5	20	0.00	0.00	
Mean ± SD		37.69 ± 12.67		47.92 ± 14.91		28.84 ± 11.05		

Sig: at P<0.05, 0.01; NS: at P>0.05; testing is based on a Contingency Coefficient test.

Table 2: Site of CLN involvement and CLN shape distribution among studied groups with testing significant

Lymph Node Shape and Sites		Control		Non Hodgkin Lymphoma		Hodgkin Lymphoma		C.S. (*) P-value
		No.	%	No.	%	No.	%	
Lymph Node Shape	Oval	22	75.9	14	29.8	10	22.2	CC=0.405 P= 0.000 Si
	Round	7	24.1	33	70.2	35	77.8	
Parotid		4	13.8	3	6.4	5	11.1	CC=0.355 P= 0.359 NS
Sub Mental		4	13.8	1	2.1	1	2.2	
Sub Mandibular		6	20.7	9	19.1	6	13.3	
Upper Cervical		0	0.00	6	12.8	6	13.3	
Middle Cervical		5	17.2	8	17.0	5	11.1	
Lower Cervical		2	6.9	4	8.5	4	8.9	
Left Supraclavicular		6	20.7	10	21.3	8	17.8	
Right Supraclavicular		1	3.4	5	10.6	5	11.1	
Posterior Triangle		1	3.4	1	2.1	5	11.1	
Total		29	100	47	100	45	100	

Sig: at P<0.05, 0.01; NS: Non-Sig. at P>0.05; testing is based on a Contingency Coefficient test.

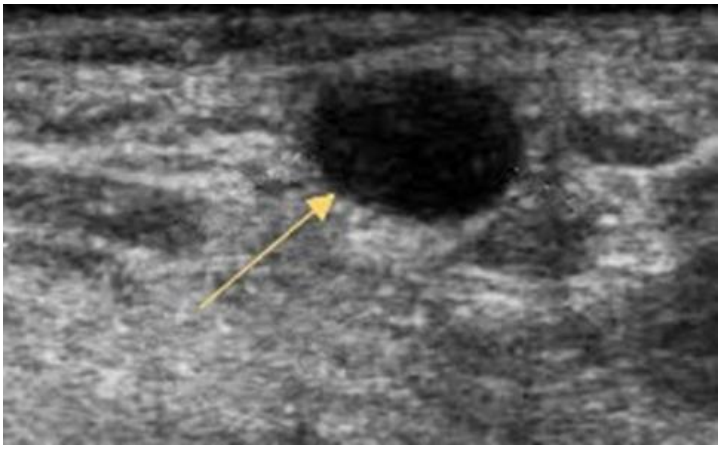

Figure 2: Round enlarged lymphomatous cervical lymph node

The results in Table 3 showed that control group presented with 82.8% intact fatty Hilum, while 27.7% and 20% in NHL and HL groups, respectively, that (Si) relationships were obtained at P=0.000 between control and NHL, HL groups, and (NS) difference at P=0.389 are proved between NHL, HL groups, also in Table 3 cystic necrosis parameter outcomes (present or absent), results showed that 6.9% present in control group while 44.7% and 24.4% present in NHL and HL, respectively, that (Si) relationships were obtained at P=0.000 between controlled and NHL group, with NS relation between HL and control groups at P=0.053 and (Si) relationship between NHL, HL groups at P=0.042, while (NS) relation achieved for coagulation necrosis and internal calcification at P=0.280, P=0.071, respectively.

Figure 3 displays the normal cervical lymph node with echogenic hilum.

Regarding Nodal Border, the results in Table 4 showed control group 55.2% with regular lymph node border, while it was 78.7% and 68.9% for NHL and HL, respectively, that (Si) relationship was obtained at P=0.030 between controlled and NHL group and (NS) relationships at P=0.096 with the leftover comparisons, but rather than distribution of regular or irregular cases among studied groups indicated (NS) relationship at P=0.231, but according to the observed significant level P=0.096, it is more informative for that result to reported for HL, rather than simply stating that significant level was not

achieved [11]. With respect to homogeneity results showed 100% of control group CLN were heterogeneous, while it was 78.7% and 77.8% for NHL and HL groups, respectively, that (Si) relationships were obtained at P=0.008 and P=0.006 among control and the NHL, HL groups, and (NS) at P=0.912 between NHL and HL groups. Finally, with respect to lymph node status related to adjacent tissue results showed 100% of CLN in control group were discrete, while 42.6% of lymphomatous CLN in NHL group were matted. Therefore, it was 22.2% in HL group, that (Si) relationships were obtained at P=0.000 and P=0.006 between controlled and NHL, HL groups, as well as (Si) relationship was reported at P=0.038 between distribution outcomes concerning NHL, HL groups, Table 4 and Figure 4 illustrate matted cervical lymph nodes.

Table 3: Distribution of Gray Scale US CLN parameters (fatty hilum, cystic necrosis, coagulation necrosis, and internal calcification) with testing significant

Parameters	Resp.	Control (I)		NHL (II)		HL (III)		C.S. (*) P-value	
		No.	%	No.	%	No.	%	I X II I X III IIXIII	CC-value
Fatty Hilum	Present	24	82.8	13	27.7	9	20.0	P=0.000 Si P=0.000 Si	CC=0.463 P=0.000 Si
	Absent	5	17.2	34	72.3	36	80.0	P=0.389 NS	
Cystic Necrosis	Present	1	6.9	21	44.7	11	24.4	P=0.000 Si P=0.053 NS	CC=0.313 P=0.001 Si
	Absent	27	93.1	26	55.3	34	75.6	P=0.042 Si	
Coagulation Necrosis	Present	0	0.00	3	6.4	1	2.2	P=0.165 NS	CC=0.144 P=0.280 NS
	Absent	29	100	44	93.6	44	97.8	P=0.419 NS P=0.328 NS	
Internal Calcification	Present	0	0.00	6	12.8	2	4.4	P=0.045 Si	CC=0.204 P=0.071 NS
	Absent	29	100	41	87.2	43	95.6	P=0.250 NS P=0.157 NS	

Sig: at P<0.05, 0.01; NS: at P>0.05; testing is based on a Contingency Coefficient test.

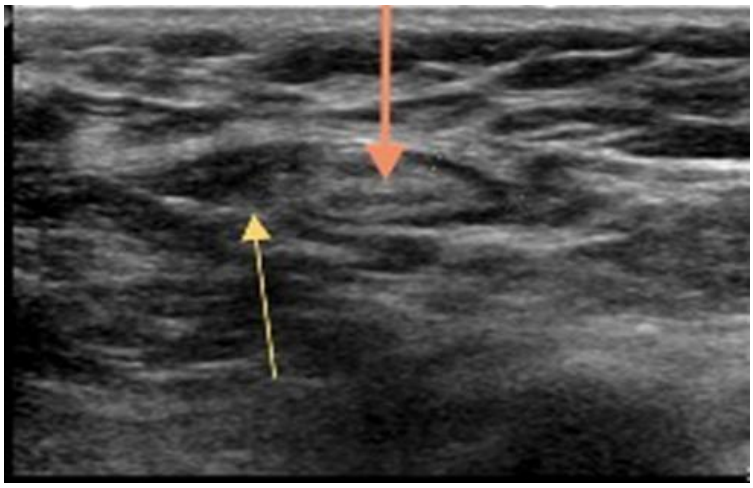

Figure 3: Normal oval cervical lymph node (yellow arrow), intact echogenic hilum (orange arrow)

Table 4: Distribution of Gray-Scale US CLN parameters (nodal border, homogeneity, and lymph node status in relation to the adjacent tissue) with the testing significant

Lymph Node Properties	Resp.	Control (I)		NHL (II)		HL (III)		C.S. (*) P-value	
		No.	%	No.	%	No.	%	I X II I X III IIXIII	CC-value
Nodal Border	Regular	16	55.2	37	78.7	31	68.9	P=0.030 Si P=0.231 NS	CC=0.193 P=0.096 NS
	Irregular	13	44.8	10	21.3	14	31.1	P=0.283 NS	
Homogeneity	Homo.	0	0.00	10	21.3	10	22.2	P=0.008 Si	CC=0.243 P=0.023 Si
	Hetero.	29	100	37	78.7	35	77.8	P=0.006 Si P=0.912 NS	
Lymph node status related to adjacent tissue	Matted	0	0.00	20	42.6	10	22.2	P=0.000 Si	CC=0.357 P=0.000 Si
	Discrete	29	100	27	57.4	35	77.8	P=0.006 Si P=0.038 Si	

(*)Sig: at P<0.05, 0.01; NS: at P>0.05; testing is based on a Contingency Coefficient test.

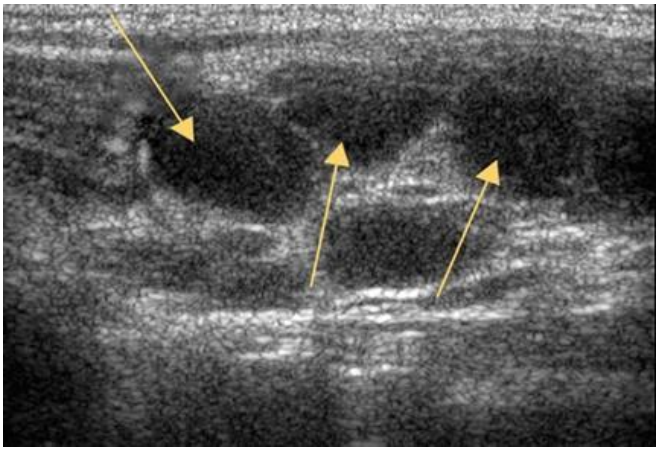

Figure 4: Group of lymphomatous cervical lymph nodes fused together (matted)

Regarding echogenic pattern in Table 5, hypoechoic pattern the percentages were in control group (72.4%), NHL group (78.7%) and HL group (68.9%) that was (NS) at P=0.530, hyperechoic pattern the percentages were in control group (27.6%), NHL group (6.3%), and HL group (11.1%) with (Si) relationship between studied groups at P=0.011, Isoechoic pattern. There was (NS) at P=0.068, which appear with 4.3% in NHL group and 0.0% in HL and control groups, reticular pattern (Figure 5A, B, and C), which was presented with (20%) in HL and (10.6%) in NHL with (Si) at P=0.003 to control group which was presented with 0.0%.

Age and gender

The present study showed an increase in female patients in the HL group, while male patients were the highest registered in the NHL group; this is in line with *Touma et al*. [12]. They stated that the NHL occurrence was observed more in males than females, while the HL occurrence in males was slightly more than females. On the other hand, *Huang et al.* [13] and the *Cancer.Net Editorial Board* [14] stated that NSHL of CHL is frequently developed in females.

Concerning NHL patient's age, the results are compatible with the *UK Cancer Research* [15] as stated that the age-specific incidence rates increase steadily and start around the age of (45-49) years old and more dramatically start around the age of (55-59) years old.

Table 5: Distribution of Gray-Scale US parameter "Echogenic pattern" in studied Groups" with comparison's significant

Echogenicity	No. & %			HL	CS P-value	CS P-value
		control	NHL			
Hypoechoic	No	21	37	31	P=0.530 NS	CC=0.341 P= 0.014 (Si)
	%	72.4%	78.7%	68.9%		
Hyperechoic	No	8	3	5	P=0.011 Si	
	%	27.6%	6.4%	11.1%		
Isoechoic	No	0	2	0	P=0.068 NS	
	%	0.00%	4.3%	0.00%		
Reticular Echogenicity	No	0	5	9	P=0.003 Si	
	%	0.00%	10.6%	20.0%		
Total	No	29	47	45	-	
	%	100%	100%	100%		

(*) Sig: at P<0.05, 0.01; NS: Non-Sig. at P>0.05; testing is based on Fisher's Exact test, and a Contingency Coefficient test.

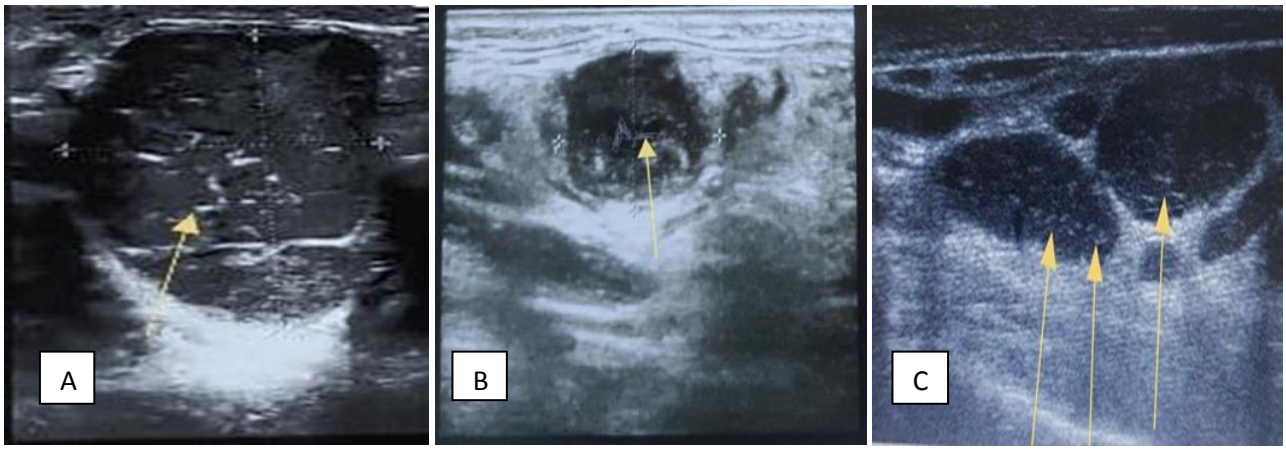

Figure 5: Lymphomatous enlarged cervical lymph nodes with reticular (micro-nodular) echogenic pattern (yellow arrows)

Regarding the age of the HL group, the results are compatible with *Ananya* [16] who mentioned that HL is most common in the early adulthood (especially in a person's 20s) and typically occurs in two age classes, specifically those between the ages 15 and 35 and those above the age of 55 years, respectively.

Lymph node shape

George and Appukuttan [17] mentioned that the nodal shape is an essential US parameter to distinguish different pathologic lesions, *Osanai et al.* [18] pointed out that lymph node with an S/L < 0.5 mm is oval in shape and demonstrates normality, while S/L ≥ 0.5mm seems round in shape that most commonly referred to pathologic lymph node, nonetheless, the S/L ratio of the normal submandibular nodes is often more than or equal to 0.5 mm, *Ying and Ahuja* [19], also they stated in 2005 that the parotid and submandibular lymph nodes, commonly have a shape round (S/L ≥ 0.5).

The results showed that lymph node shape (round) presented in NHL and HL groups as a (predictive clinical feature) more than the control group, while there was no evidence that there was a difference between NHL and HL groups and this agrees with *Kartal, Ataş, and Gürsel* [20] and *Bo Wang et al.* [21], also it should be taken in consideration that in an early stage of malignancy, the lymphomatous CLN may have an oval shape, *Craig, Brook, and Lewis* [22].

Lymph node border

In this study, the results showed that there was evidence that lymph node border (regular) more occurred in lymphomatous CLN in NHL patients than normal CLN in healthy and HL groups, but it

is informative (not statistically dependent) regarding HL group [11], some studies imply that malignant lymph nodes have a regular border on ultrasonography, whereas benign nodes appear to have irregular borders. There has been debate over the nodal border and its relationship to malignancy [22].

Respecting control group, the result agrees with *Al-Ani, Mashlah, and Al-Hafar* [23] and concerning NHL and HL groups, the results were compatible with *AT Ahuja et al*. [24], *Shahad, Taghreed, and Mohammed* [4, 25], the latter in their study realized that benign lymph nodes often have irregular borders, while malignant lymph nodes typically have normal borders (including metastases and lymphoma).

Regular lymph node border of malignant lymph nodes in the US supposed that as a result of infiltrating tumor cells, which substitute malignant cells for the normal intra-nodal lymphoid tissues, resulting in an increased variation in the acoustic impedance (density) between the intra-nodal and surrounding tissues, an irregular nodal border of malignant lymph node indicate extracapsular spread, *Ying. M. et al.* [26], Furthermore, *Okumuş, Dönmez*, and *Pekiner* [27], despite that their study on NHL, and HL as one group (lymphoma) which showed that 60 % of malignant CLN with regular borders is not useful in the differential diagnosis.

Site of involvement

The results are compatible with *Mohseni et al.* [25, 28] as they found in their study that the most sites of involvement for lynphomatous CLN in lymphoma were supraclavicular, submandibular, middle cervical, lower cervical, and posterior triangle level, respectively.

Other studies found results that are different from the results of the current study, like that of *Sakr* [24, 29] as they mentioned that the involved CLN are commonly located at the submandibular, upper cervical, and posterior triangle levels.

Also, *David et al.* [30], observed that the submental, submandibular, and posterior triangle levels, the most associated lymph nodes in their study on 19 patients with malignant cervical lymphadenopathy, this may narrows the differential diagnosis to lymphoma and metastases from mouth cavity malignancies, while [22] stated that lymphomatous CLN in lymphoma most commonly found at the submandibular, and upper cervical levels, regarding to the current study there was significant percentage for submandibular and upper cervical regions involvement (30%) and (24%), respectively.

Fatty hilum

Normal lymph nodes can appear on sonography without fatty hilum (avascular) due to their smaller size [31]. The result was fatty hilum (absent) presented in lymphomatous CLN in NHL and HL patients as a (predictive clinical feature), with no difference obtained between NHL and HL groups, the result on line with *Dangore, Degweka, and Bhowate* [17, 32], they mentioned absent fatty hilum in lymphomatous CLN with approximately the same result. Furthermore, they mentioned that fatty hilum is important indicator to differentiate between benign and malignant lymph node and regarding normal CLN in the control group, the result was in line with the study conducted by *Ying et al.* [33].

Cystic necrosis

The result in this study was that cystic necrosis (present) presented in CLN of NHL patients as a (predictive clinical feature) with presented cases more than the HL and control groups, with no difference obtained between the HL and control group, but we should keep that there was a percentage of present cases in the HL group, our result agree with the study of [9, 17], and the study performed by *Chae et al*. [34], while [20] and *Mohamed, Tamer, and Haney* [35] in their studies they found the percentage of cystic necrosis (present) more than the current study.

Necrosis occurs when the tumor cells inside a lymph node outgrow their blood supply and most frequently take the form of cystic pattern within the node that shows up as echolucent patches on sonography [22], and even so the lymph node is large or normal in size, the presence of intranodal necrosis should be considered pathologic [24].

Coagulation necrosis

The results are consistent with *Pattanayak et al.* [34, 36] that weakness of the presents cases and coagulation necrosis is uncommon in lymphomatous CLN.

Xiaoyin et al. [37] mentioned that coagulation necrosis (infraction) takes place due to rapidly growing neoplasm and observed a few cases with coagulation necrosis especially in diffuse Large B-Cell Lymphoma (DLBCL).

Internal calcification

The results were in line with *Marchiori et al*. [17, 34, 38], as they stated that internal calcification, is uncommon in lymphomatous CLN.

Kachewar [39] stated that lymphomatous CLN calcification is rarely seen and the most frequent cause of internal calcifications is granulomatous infection, particularly tuberculosis (TB) and less frequent occurrences are linked to the therapy of lymphomas (radiation therapy or chemotherapy) [38].

Lymph node status in relation to the adjacent tissue (Matted/Discrete)

Matted showed as a clump of lymph nodes coalesces or adheres to nearby tissue, it is referred to as having "matted lymph nodes", these conditions can be benign (such as TB infection and sarcoidosis) or malignant (such as lymphoma and metastatic cancer) [28].

The result regarding this parameter as (matted), presented as predictive clinical feature and the most common in the involved CLN of NHL, HL, at the same time, there was evidence that it presented in the NHL more than HL groups, this result agrees with [28, 35].

Matting lymph nodes occurrences is either as a result of tumor cell infiltration or as an inflammatory reaction of adjacent tissues, it considers the characteristic of tuberculous lymph nodes, and uncommon in lymphomatous nodes [4], furthermore they mentioned that adjacent soft tissues can be invaded by malignant lymph nodes with extra capsular dissemination, which can cause tissue edema.

Homogeneity

The parameter homogeneity (homogenous) presented with clinical evidence that it was a predictive clinical feature in involved CLN of NHL and HL groups, while there was no evidence for the difference between NHL and HL groups, this result agrees with [20, 35].

Abhishek et al. [34, 40] observed homogenous lymphomatous CLN cases more than that in the current study.

Regarding the homogeneity area, the sonographic appearance of lymph node either homogenous or heterogenous and it can appear in both benign and malignant lymph nodes, in the homogenous hypoechoic benign lymph node, the hypoechogenicity is normal lymphatic tissue, while the malignant lymph nodes with a homogeneous hypoechoic pattern could be explained by the fact that the internal structures of the lymph node are distorted by degeneration due to neoplastic cells infiltration, heterogeneous pattern in the malignant lymph nodes demonstrated to be a mixture of severe fibrosis, and degeneration necrosis *Toriyabe et al.* [41].

Echogenic pattern (echogenicity)

Echogenicity of the tissue refers to the capacity of the tissue to reflect or transmits the US waves in proportion to surrounding tissues, *Ihnatsenka and Boezaart*, so there are varied densities of soft tissue structures with different echogenicities, and thus there will be a noticeable variation in contrast to the sonogram image.

In relation to hypoechoic pattern and regarding the control group, the result is compatible with [23, 27] and regarding NHL and HL group, the result was consistent with [9, 17].

Regarding hyperechoic pattern, the result is in agreement with [9, 17, 23, 24].

The Isoechoic pattern was presented with no evidence obtained about the difference between the studied group and this result agrees with the study of [9, 35].

Finally, the reticular pattern which was presented with evidence that it was a predictive clinical feature in the involved CLN in NHL and HL patients, besides there was no difference

between the NHL and HL groups, our result was in agreement with *Ahuja et al*. [9, 19, 21].

Conclusion

The study showed an increase in female patients diagnosed with HL within the study sample, while male patients were the highest registered with NHL. Furthermore, most of the patients diagnosed with NHL were at the third-forth stage at the time of diagnosis, while the most of the HL patients were at first-third stage. Gray-scale US parameters of CLN: lymph node shape (round), fatty Hilum (absent), lymph node status in relation to the adjacent tissue (matted), homogeneity (homogenous), and reticular pattern were diagnostic indicators to predict occurrence of NHL and HL, while no difference was obtained between NHL and HL groups regarding gray-scale US parameters above, with more presented matted lymph nodes in the NHL than HL group.

With respect to cystic necrosis (present) was diagnostic indicator to NHL, while it presented with fewer cases in the HL that no statistical difference was found between HL and the control group. Concerning lymph node border (regular) was the diagnostic feature in NHL group, while for the HL group; it is informative in contrast to the control group. In relation to coagulation necrosis, internal calcification, hypoechoic pattern, and isoechoic pattern presented with no difference between studied groups. Sites of involvement, the most site of the involved CLN in the NHL and HL groups were in the left supraclavicular (Virchow), submandibular, middle cervical, upper cervical, right supraclavicular, parotid, lower cervical, posterior triangle, and sub mental CLN regions. Finally, hyperechogenicity was prominent in the control group more than that in the HL and NHL groups.

Funding

The study was approved by the College of Dentistry Ethics Committee of Baghdad University (Project No. 632722). Written informed consent was obtained from participants in this study.

Authors' contributions

All authors contributed to data analysis, drafting, and revising of the paper and agreed to be responsible for all the aspects of this work.

Conflict of Interest

The author declared that they have no conflict of interest.

ORCID:

Ammar Jalil Sebahi
https://orcid.org/0000-0002-8657-3349

References

[1]. Moore K.L., Agur A.M.R., Dalley A.F., Clinically Oriented Anatomy, Eighth edition, International ed. Wolters Kluwer, 2018, 43 [Publisher]

[2]. Grujičić R., Lymphatic system[internet], Ken Hub. academic literature and research, berlin[Last reviewed: [October 15, 2021 cited 2022 Jan 5 [Google Scholar], [Publisher]

[3]. Bontumasi N., Jacobson J.A., Caoili E., Brandon C., Kim S.M., Jamadar D., Inguinal lymph nodes: size, number, and other characteristics in asymptomatic patients by CT, *Surgical and Radiologic Anatomy*, 2014, **36**:1051 [Crossref], [Google Scholar], [Publisher]

[4]. Jaiswal P., Sharma P., Value of ultrasound in evaluation of cervical lymphadenopathy: correlation with FNAC/histopathology, *Journal of Society of Surgeons of Nepal*, 2016, **19**:13 [Crossref], [Google Scholar], [Publisher]

[5]. Khanna R., Sharma A.D., Khanna S., Kumar M., Shukla R.C., Usefulness of ultrasonography for the evaluation of cervical lymphadenopathy, *World journal of surgical oncology*, 2011, **9**:29 [Crossref], [Google Scholar], [Publisher]

[6]. Ramadas A.A., Jose R., Varma B., Chandy M.L., Cervical lymphadenopathy: Unwinding the hidden truth, *Dental Research Journal*, 2017, **14**:73 [Crossref], [Google Scholar], [Publisher]

[7]. Abdelgawad E.A., Abu-samra M.F., Abdelhay N.M., Abdel-Azeem H.M., B-mode ultrasound, color Doppler, and sonoelastography in differentiation between benign and malignant cervical lymph nodes with special emphasis on sonoelastography, *Egyptian Journal of Radiology*

and Nuclear Medicine, 2020, **51**:157 [Crossref], [Google Scholar], [Publisher]

[8]. Doğan S., Yildirim A., Erbakırcı R., Okur A., Çağlı S.E.D.A.T., Mavili E., Yüce İ.M.D.A.T., Guney E., Öztürk M., The role of ultrasonography for differentiating and management of malignant cervical lymph nodes, *European Journal of General Medicine*, 2016, **13**:7 [Crossref], [Google Scholar], [Publisher]

[9]. Sapkota S., Shaikh H., Non-Hodgkin Lymphoma. [Updated 2022 May 1]. In: StatPearls [Internet]. Treasure Island (FL): StatPearls Publishing [Publisher]

[10]. Nordness RJ. Epidemiology and biostatistics secrets. Philadelphia, PA: Mosby Elsevier; 2006 [Publisher]

[11]. Touma E., Antoun L., Hallit S., Nasr F., Massoud M., El Othman R., Chahine G., Non Hodgkin lymphoma in Lebanon: a retrospective epidemiological study between 1984 and 2019, *BMC Public Health*, 2021, **21**:1820 [Crossref], [Google Scholar], [Publisher]

[12]. Huang J., Pang W.S., Lok V., Zhang L., Lucero-Prisno D.E., Xu W., Zheng Z.J., Elcarte E., Withers M., Wong M., Incidence, mortality, risk factors, and trends for Hodgkin lymphoma: a global data analysis, *Journal of hematology & oncology*, 2022, **15**:57 [Crossref], [Google Scholar], [Publisher]

[13]. Cancer.Net. Lymphoma – Hodgkin: Introduction, 2022 [Publisher]

[14]. Ananya Mandal. Hodgkin's Lymphoma Epidemiology[internet], News-Medical.Net, 2019 [Publisher]

[15]. George P., Appukuttan A.J., Evaluation of Ultrasonography and Colour Doppler in Cervical Lymphadenopathy Taking Histopathology as Comparison, *Journal of Evolution of Medical and Dental Sciences*, 2021, **10**:1391 [Google Scholar], [Publisher]

[16]. Osanai H., Kuroiwa H., Uchida K., Kagami H., Yamada K., Taguchi A., Sonographic appearances of cervical lymph nodes in healthy young Japanese adults: Association with age, sex, and body mass index, *Journal of Clinical Ultrasound*, 2015, **43**:295 [Crossref], [Google Scholar], [Publisher]

[17]. Ying M., Ahuja A., Sonography of neck lymph nodes. Part I: normal lymph nodes, *Clinical radiology*, 2003, **58**:351 [Crossref], [Google Scholar], [Publisher]

[18]. Kartal Ö., Ataş E., Gürsel O., Differentiation of benign from malignant cervical lymphadenopathy by ultrasonography in children, *Archivos Argentinos de Pediatria*, 2020, **118**:11 [Crossref], [Google Scholar], [Publisher]

[19]. Wang B., Zhang M.K., Zhou M.P., Liu Y., Li N., Liu G., Wang Z.L., Logistic Regression Analysis of Conventional Ultrasound, and Contrast-Enhanced Ultrasound Characteristics: Is It Helpful in Differentiating Benign and Malignant Superficial Lymph Nodes?, *Journal of Ultrasound in Medicine*, 2021, **41**:343 [Crossref], [Google Scholar], [Publisher]

[20]. Giacomini C.P., Jeffrey R.B., Shin L.K., Ultrasonographic evaluation of malignant and normal cervical lymph nodes. In *Seminars in Ultrasound, CT and MRI*, WB Saunders, 2013, **34**:236 [Crossref], [Google Scholar], [Publisher]

[21]. Al-Ani R.S., Mashlah A.M., Al-Hafar M.I., Sonographic assessment of normal cervical lymph nodes in a sample of Syrian population, *Journal of Baghdad College of Dentistry*, 2014, **25**:94 [Google Scholar], [Publisher]

[22]. Ahuja A.T., Ying M., Ho S.Y., Antonio G., Lee Y.P., King A.D., Wong K.T., Ultrasound of malignant cervical lymph nodes, *Cancer Imaging*, 2008, **8**:48 [Crossref], [Google Scholar], [Publisher]

[23]. Ali S.D., Zaidan T.F., Mahdi M.A., Evaluation of the efficacy of ultrasound in the diagnosis of cervical lymphadenopathy, *Journal of Baghdad College of Dentistry*, 2018, **30**:59 [Crossref], [Google Scholar], [Publisher]

[24]. Ying M., Bhatia K.S.S., Lee Y.P., Yuen H.Y., Ahuja A.T., Review of ultrasonography of malignant neck nodes: greyscale, Doppler, contrast enhancement and elastography, *Cancer imaging*, 2014, **13**:658 [Crossref], [Google Scholar], [Publisher]

[25]. Okumuş Ö., Dönmez M., Pekiner F.N., Ultrasonographic Appearances of Cervical Lymph Nodes in Healthy Turkish Adults Subpopulation: Preliminary Study, *The open dentistry journal*, 2017, **11**:404 [Crossref], [Google Scholar], [Publisher]

[26]. Mohseni S., Shojaiefard A., Khorgami Z., Alinejad S., Ghorbani A., Ghafouri A., Peripheral lymphadenopathy: approach and diagnostic tools, *Iranian journal of medical sciences*, 2014, **39**:158 [Google Scholar], [Publisher]

[27]. Sakr M., Cervical: Lymphadenopathy, *Head and Neck and Endocrine Surgery*, 2016, **9**:163 [Crossref], [Google Scholar], [Publisher]

[28]. David S.K., Joseph B.A., Easwarapillai B.K., Varma R.R., Proportion of malignancy in cervical lymphadenopathy, *International Surgery Journal*, 2017, **4**:3378 [Crossref], [Google Scholar], [Publisher]

[29]. Prativadi R., Dahiya N., Kamaya A., Bhatt S., October. Ultrasound characteristics of benign vs malignant cervical lymph nodes, In *Seminars in Ultrasound, CT and MRI*, WB Saunders, 2017, **38**:506 [Crossref], [Google Scholar], [Publisher]

[30]. Dangore S.B., Degwekar S.S., Bhowate R.R., Evaluation of the efficacy of colour Doppler ultrasound in diagnosis of cervical lymphadenopathy, *Dentomaxillofac Radiol*, 2008, **37**:205 [Crossref], [Google Scholar], [Publisher]

[31]. Ying M., Bhatia K.S., Lee Y.P., Yuen H.Y., Ahuja A.T., Review of ultrasonography of malignant neck nodes: greyscale, Doppler, contrast enhancement and elastography, *Cancer Imaging*, 2014, **13**:658 [Crossref], [Google Scholar], [Publisher]

[32]. Chae S.Y., Jung H.N., Ryoo I., Suh, S., Differentiating cervical metastatic lymphadenopathy and lymphoma by shear wave elastography, *Scientific reports*, 2019, **9**:12396 [Crossref], [Google Scholar], [Publisher]

[33]. Elbadry M.S., Mohammad M.A., Benign Versus Malignant Cervical Lymph Nodes; Differentiation by Diffusion Weighted MRI, *Benha Medical Journal*, 2022, **39**:194 [Crossref], [Google Scholar], [Publisher]

[34]. Pattanayak S., Chatterjee S., Ravikumar R., Nijhawan V.S., Sharma V., Debnath J., Ultrasound evaluation of cervical lymphadenopathy: Can it reduce the need of histopathology/cytopathology?, *medical journal armed forces india*, 2018, **74**:227 [Crossref], [Google Scholar], [Publisher]

[35]. Jiang X., West D.S., Lagoo A.S., Lymph Node Infarction Is Strongly Associated With Malignancy, *American Journal of Clinical Pathology*, 2012 **138**:A042 [Crossref], [Google Scholar], [Publisher]

[36]. Marchiori E., Hochhegger B., Zanetti G., Lymph node calcifications, *J Bras Pneumol*., 2018, **44**:83 [Crossref], [Publisher]

[37]. Kachewar S., Lymph node calcifications: The processes, determinants and health impacts. Calcification Processes, *Determinants and Health Impact*, 2013, 127 [Google Scholar], [Publisher]

[38]. Gupta A., Rahman K., Shahid M., Kumar A., Qaseem S.D., Hassan S.A., Siddiqui F.A., Sonographic assessment of cervical lymphadenopathy: Role of high-resolution and color Doppler imaging, *Head & neck*, 2011, **33**:297 [Crossref], [Google Scholar], [Publisher]

[39]. Toriyabe Y., Nishimura T., Kita S., Saito Y., Miyokawa N., Differentiation between benign and metastatic cervical lymph nodes with ultrasound, *Clinical radiology*, 1997, **52**:927 [Crossref], [Google Scholar], [Publisher]

[40]. Ihnatsenka B., Boezaart A.P., Ultrasound: Basic understanding and learning the language. *International journal of shoulder surgery*, 2010, **4**:55 [Crossref], [Google Scholar], [Publisher]

[41]. Ahuja A.T., Ying M., Yuen H.Y., Metreweli C., 'Pseudocystic' appearance of non-Hodgkin's lymphomatous nodes: an infrequent finding with high-resolution transducers, *Clinical radiology*, 2001, **56**:111 [Crossref], [Google Scholar], [Publisher]

HOW TO CITE THIS ARTICLE

Ammar jalil sebahi, Fawaz Al-Asawad. Gray-Scale Ultrasonographic Features of Cervical Lymph Nodes in Patients with Newly Diagnosed Hodgkin and Non-Hodgkin Lymphoma. *J. Med. Chem. Sci.*, 2023, 6(5) 1180-1192
https://doi.org/10.26655/JMCHEMSCI.2023.5.24
URL: http://www.jmchemsci.com/article_160188.html