



Original Article

Medical and Pharmacological Evaluation of Scar Formation in Plastic Surgery

Hamidreza Alizadeh Otaghvar^{1,*}, Farnaz Amini^{2,*}, Majid Pouya³, Saeid Pakseresht³, Mostafa Dahmardehei⁴, Aliakbar Jafarian⁵, Maryam Milanifard⁶

¹Associated Professor of Plastic Surgery, Truma and Injury Research Center, Iran University of Medical Sciences, Tehran, Iran

²General Practitioner, Tonekabon Islamic Azad University of Medical Sciences, Tonekabon, Iran

³Assistant Professor of Surgery Group of Tonekabon Islamic Azad University of Medical Sciences, Tonekabon, Iran

⁴Associate Professor of Plastic Surgery Group of Iran University of Medical Sciences, Trauma Injury Research Center of Iran University of Medical Sciences, Tehran, Iran

⁵Associate Professor of Anesthesiology, Iran University of Medical Sciences, Iran

⁶Researcher at the Anesthesia and Pain & Molecular and Cell Biology Research center, Faculty of Medicine, Department of Anatomy, Iran University of Medical Sciences, Tehran, Iran

ARTICLE INFO

Article history

Received: 2021-12-04

Received in revised: 2022-01-02

Accepted: 2022-01-04

Manuscript ID: JMCS-2112-1359

Checked for Plagiarism: Yes

Language Editor:

Ermia Aghaie

Editor who approved publication:

Dr. Ali H. Jawad Al-Taie

DOI:10.26655/JMCHMSCI.2022.4.1

KEYWORDS

Mastopexy Scar

Butax

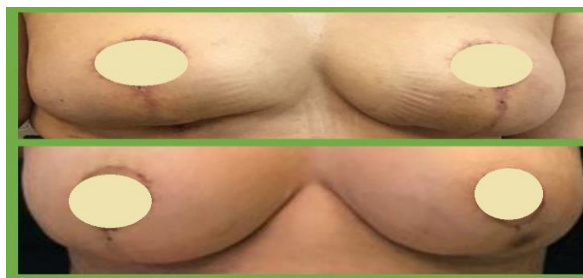Vancouver Scale

Injected groups

ABSTRACT

Scar management is a critical challenging object in plastic surgery that influences life quality and can induce depression and functional disturbances. Hypertrophic scars and keloids after surgery, especially in cosmetic surgeries, can cause inappropriate appearance and excess costs to decrease the scar. Moreover, spiritual disturbance and psychological problems can occur, which lead to objections against physicians. Multi-disciplinary treatments like Butax injection have been suggested. This study is a case-control type. The cases are 20 patients attending Mehr Surgical Center and Rasoul-e- Akram hospital in Tehran diagnosis of hypertrophic scars or keloids after surgical mastopexy from February 2018 to February 2019. Four characteristics like width, height, color, and pliability were studied according to surgery scar. Also, the patient's age, smoking, pleasure, and previous history of hypertrophic scars and keloids are Surveyed. In each of the patients, Butax is injected in right breast scar without any injection in the contralateral side as a control group and all patients studied for 18 months. At the end, data was analyzed with the SPSS 22 software. This study achieved meaningful differences between with and without Butax injected groups. According to Vancouver scale, the width, height, color, and pliability achieved higher scores meaningfully. In addition, the pleasure of patients in injected groups has achieved a higher score. There was a meaningful correlation between smoking and pleasure score in these patients, but we did not find a meaningful relationship with age.

GRAPHICAL ABSTRACT



* Corresponding author: Farnaz Amini

✉ E-mail: Email: Farnazamini@yahoo.com

© 2022 by SPC (Sami Publishing Company)

Introduction

Scar formation is considered an essential topic in plastic surgery. Scars induced by previous operations, burns and traumas in face and limbs area can make considerable outcomes induced by previous operations, and traumas in face and limbs can make considerable outcomes for patients [1]. There are controversies in the management of hypertrophic scars. Maxillofacial scars and neck's scars formed by benign fibers cause functional problems and aesthetic deformity within stress, pain, itching and other problems. These deformities affect the quality of life and function of patients [2]. There are acceptable results following by Botox injection on scars even with minimal alleviation. In recent years, many procedures have been used to improve scar formation [3-5]. Recent years, many procedures have been used to improve scar formation, including BTX-A injection, Laser therapy, excision, pressure therapy, and vascular endothelial cell growth inhibitors (VEGI) [6-8]. Although there are many approaches to managing scar formation, there is no evidence-based solidarity therapy. Among wound healing; applying tension on the edge of the wound affects the healing process; BTX injection induces releasing Acetyl-choline at the neuromuscular junction site [9-12].

Disfigured scars, particularly hypertrophic scars on the face area, leading to depression in the patient [13-15]. Nowadays, scars are a vitalessential aspect of aesthetics so that it can be unpleasant for the patient [16-18]. Scar formation on the face can distribute emotional expression, which is considerable due to the physical and psychological aspects [17-19]. At present, there is no efficient method to eliminate scars that probably due to limitation our knowledge [20-22]. There are many controversies about approaching hypertrophic scars especially maxillofacial and neck scars which are stressful [23-25]. These scars produced by benign fibers lead to aesthetic deformity and malfunction within physiologic stress, pain, itching, and unpredictable symptoms [26]. Deformities induced by scars decrease quality of

life, affecting the function of the patient. There are satisfying outcomess with Botox treatment following scar formation even with minimum effect [27].

Applying tension on the wound edge is the proven factor that affects wound healing also, many studies revealed that injection of botulinum toxin-A (BoNT-A) increases tension on the wound edge. The use of BTX to decrease scarcer size obeys the chemo-denervation muscles theory. Herein botulinum toxin induces releasing acetylcholine among neuromuscular junction [28]. In recent years BTX has used to correction of facial asymmetry, elimination of wrinkles, BTX has used to correct facial asymmetry, eliminate wrinkles, and correct facial asymmetry, eliminate wrinkles and decrease hypertrophic scars [29]. Hypertrophic scars caused by overproduction of fibrosis among wound healing [30] arise erythematous scar at the primary incision site. Although scars can develop during 3 or 6 months then regress, but usually get mature by horizontal expansion. BTX-A inhibition of acetylcholine in neuromuscular junction causes flaccid paralysis in skeletal muscles. This effect lasts for 6 months, so BTX-A is a treatment choice for blepharospasm, spasmodic dysphonia, and facial wrinkles [31]. Hypertrophic scars result from applying overpressure and tension on the wound site caused by the movement of body organs like upper and lower lips, forehead, and neck [8]. Movement of facial muscles leads to wrinkling appeared. Glabella lines that ensue from corrugator and procerus muscles are eliminated by botulinum toxin-A. By applying BoNT-A as a based-regular treatment, the duration of effect will increase [32].

Although the primary effect of botulinum toxin takes 3 or 4 months, it takes 6 or 7 months to disappear. Botulinum toxin-B, with a 2- or 3-months primary effect, has a more prolonged effect compared with that of the botulinum toxin-A, so BoNT-B is less useful in aesthetics. Advantage of BoNT-B is acting faster than BoNT-A; however, it has shorter-acting than BoNT-A, also BoNT-B has low ph, so it makes more pain sensation during injection [31-33]. BoNT-A and BoNT-B are used in neuralgia (cervical dystonia,

limb dystonia, and spasticity, over secretion syndromes such as scialorrea, headache, backache, writer's cramp). Most scar complications after cosmetic surgeries can tread with BoNT-A. Post-surgical scar classification is performed based on by VANCOVER SCALE. In this study, scars were assessed based on hypertrophic and keloid, so pigmentation, which is a Vancouver-scar-classification system, was not considered; therefore, another factor named "width" was examined [32].

Botulinum toxin types A and B are used to manage scars by affecting post-synaptic neurons and calcium channels in the neuromuscular junction site. Acetylcholine causes muscle contraction by opening Na/K channels in post-synaptic neuron end plate. Also, botulinum toxin binds to the axon terminal, inhibits releasing acetylcholine so causing flaccid paralysis in muscle [33].

Botulinum type B induces flaccid paralysis by inhibition of synaptobrevin. The primary response to botulinum toxin takes 3 or 4 months; however, it takes 6 or 7 months to disappear the effect [34].

Usage and types of BOTOX

TYPE-A BOTOX: It is used in dystonia, strabismus, blepharospasm, aesthetics, hyperhidrosis, and nerve VII paralysis [35].

TYPE-B BOTOX

It uses in case of dystonia, in case of resistance to TYPE-A botox, after facial laser and revision of inferior scar of the face.

Dysport

Used in dystonia and beauty.

Zeomin

Used in dystonia, strabismus, blepharospasm, and beauty [36]. Botox Type-A is prohibited in muscle paralysis, Pregnant women, patients who use amino-Glycosides, quinidine, magnesium sulfate and anti-Choline esterase, polymyxin, and sax. Either Botox types A, B, and Disport is made of unique materials. Usage of products which contain botulinum toxins in the infection of the injection site or case of hypersensitivity to botulinum toxins are contraindicated. Botulinum toxin may have a harmful effect on decreasing

respiratory function or leading to death by causing severe systemic responses.

Botox type A, B and Dysport consisting of special particular components: Botox Type A contains human albumin and sodium chloride. Botox Type B contains human albumin, Sodium chloride, and sodium succinate. Dysport includes human albumin and lactose [37].

Wound healing process contains four steps: Hemostasis, Inflammation, Proliferation, and Remodeling. Studies revealed that muscle tension occurs in the reproductive stage [38-40]. So far, many studies reveal that BTX-A can decrease the scar's width.

Methods

How to conduct a research plan before patients enter the study is explained to them, then patients begin the study after observing international ethical considerations. Written consent is required from all patients for unilateral injection into their breast surgery scar, and the forms are submitted to the ethics committee for permission. The subjects are selected from all patients with hypertrophic or colloidal scars who underwent mastopexy surgery in 96-97, and each patient is studied as a case and control. Inclusion criteria were all patients who underwent mastopexy surgery from March 96 to March 97 and suffered from hypertrophic or colloidal scars at the scar site and were referred to the Rasoul Akram Hospital clinic in Tehran Mehr Surgery Center. Both breasts had corneal scars. Patients were referred to the clinic at intervals of one week, two weeks, one month, and six weeks and were monitored for scar status. During this time, the patient was not given any anti-scar ointment, including Strataderma, Stratamed, and Contractubex, and the patients were examined for the condition of the wound. Six weeks after the patients' last visit to the clinic, patients with hypertrophic or colloidal scars were injected with Botox Canitox. We injected Botox in each patient's right breast. No injection was given in the left breast. In each patient, 50 units of Botox Knitox were diluted in 5.1 cc of distilled water and injected intradermally.

Again, three weeks and six weeks after Botox injection, patients were examined and observed according to Vancouver criteria. At each visit to the clinic, scars were photographed, and Vancouver criteria were reviewed during the visit. Vancouver scale is a post-surgery scar screening method that scores scars. In patients who underwent mastopexy surgery after Botox injection of Canitox in the scar area, we determined the condition of the scar and its scoring. We measured four criteria of width, height, color, and pliability based on Vancouver criteria during the study. The status of scars is entered in the relevant tables, and we will perform the corresponding analysis based on the software. Therefore, in this study, we want to investigate the effect of Botox injection of Knitox in reducing scars caused by cosmetic breast surgeries (mastopexy). If this drug is effective in reducing the volume of scars, it can be used in cosmetic and non-cosmetic surgeries as a scar reducer.

Results and Discussion

A) Width analysis with and without Botox injection:

The data obtained from the width analysis with and without Botox injection are in diagrams 1 and 2.

In the case of the width variable, the average in non-Botox injection is 3.175 and in Botox injection is 1.400. That is, the average width is reduced with Botox injections.

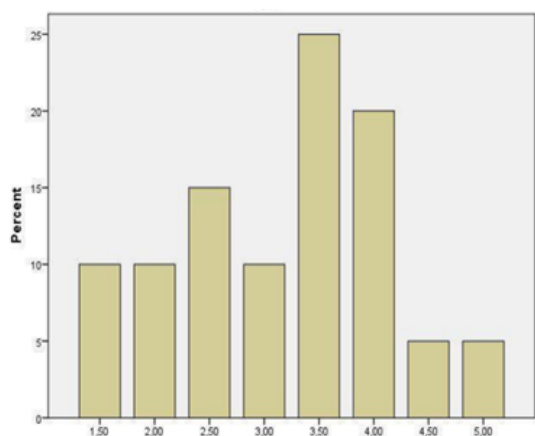


Figure 1: Width analysis without Botox injection

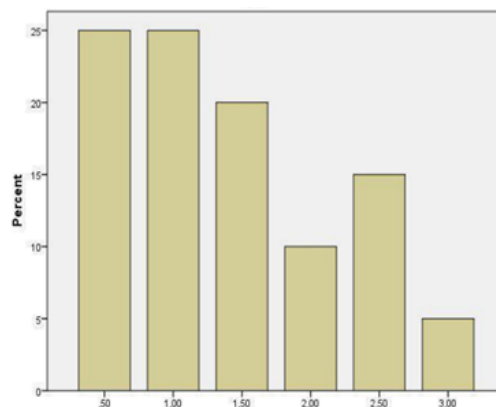


Figure 2: Width analysis with Botox injection
B) Height analysis with and without Botox injection:

The data obtained from the height analysis with and without Botox injection are in Diagrams 3 and 4.

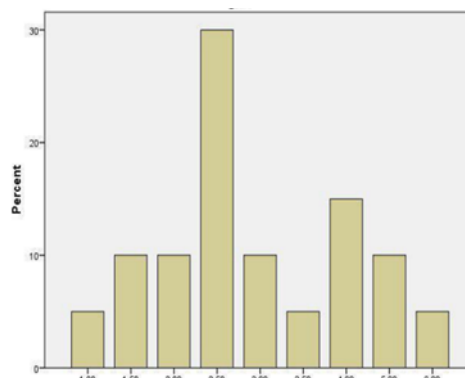


Figure 3: Height analysis without Botox injection

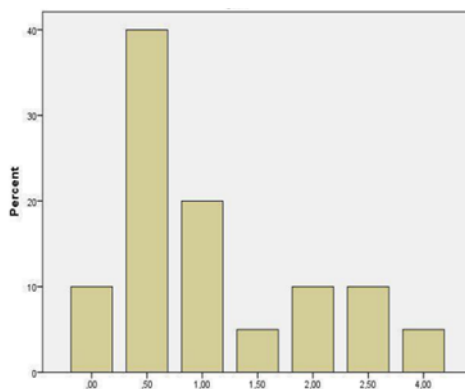


Figure 4: Height analysis with Botox injection
In the case of the height variable, the average in the non-Botox injection is 3.025 and in Botox injection is 1.125. That is, with the injection of Botox, the average height has decreased.

C) Color analysis with and without Botox injection:

The data obtained from color analysis with and without Botox injection are shown in Figures 5 and 6.

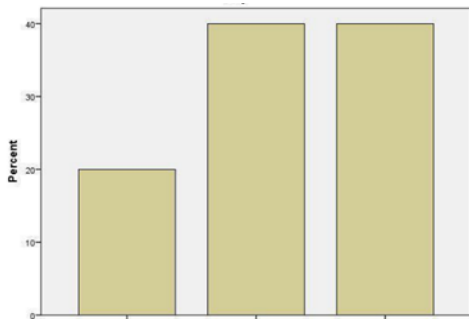


Figure 5: Color analysis without Botox injection

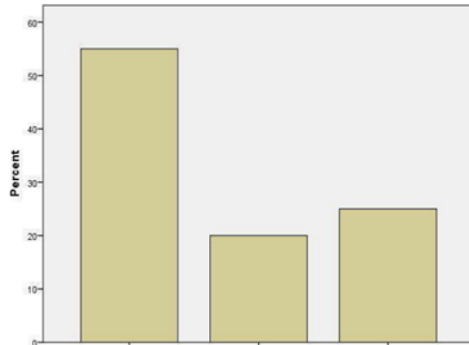


Figure 6: Color analysis by Botox injection

D) Flexibility analysis with and without Botox injection:

The data obtained from the flexibility analysis with and without Botox injection are demonstrated in Figures 7 and 8.

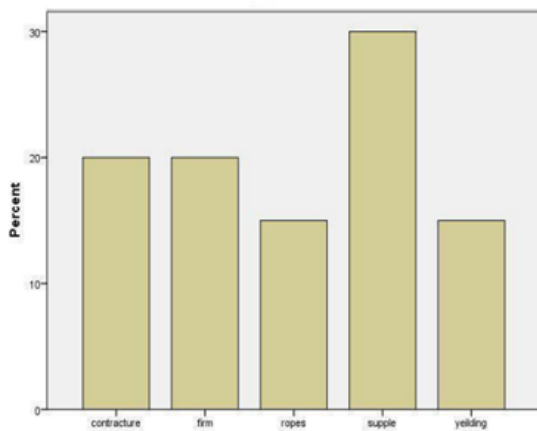


Figure 7: Flexibility analysis without Botox injection

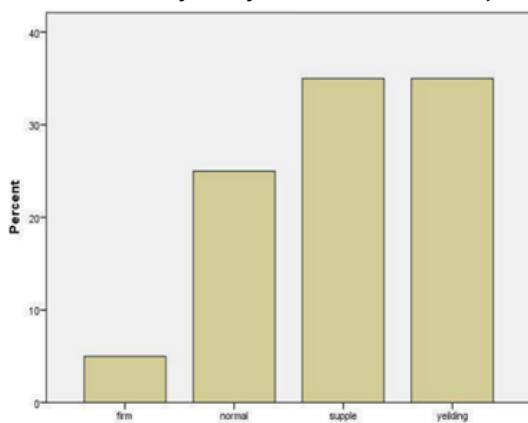


Figure 8: Flexibility analysis with Botox injection

E) Comparative analysis of color and flexibility with and without Botox injection

A comparison of colors with and without Botox injection is shown in Figure 9.

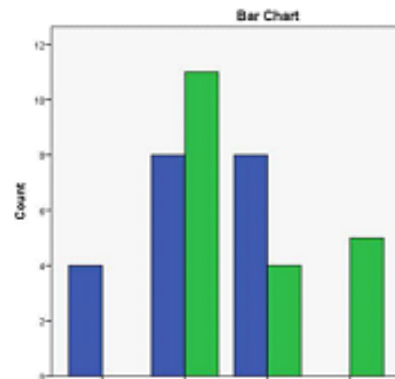


Figure 9: Color comparison with and without Botox injection

A comparison of flexibility with and without Botox injection is shown in Figure 10.

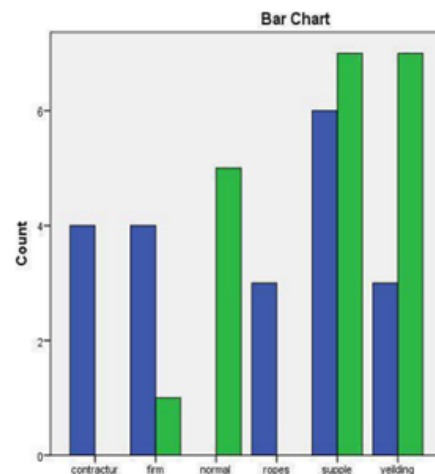


Figure 10: Comparison of flexibility with and without Botox injections

F) Analysis of the age of the subjects and smoking status:

The frequency of age of the subjects is depicted in Figure 11.

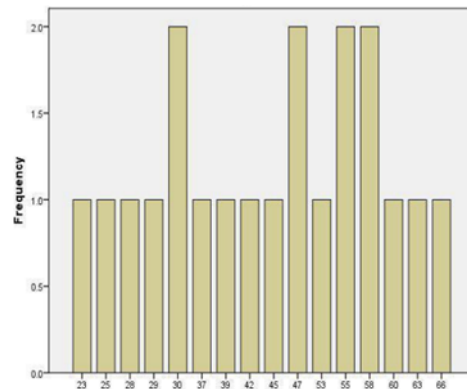


Figure 11: Frequency of age of the studied subjects

According to the findings of Figure 11, the mean age of the subjects is 44.5 years, the minimum age is 23 years, and the maximum age is 66 years. The frequency of smoking of the subjects is presented in Figure 12.

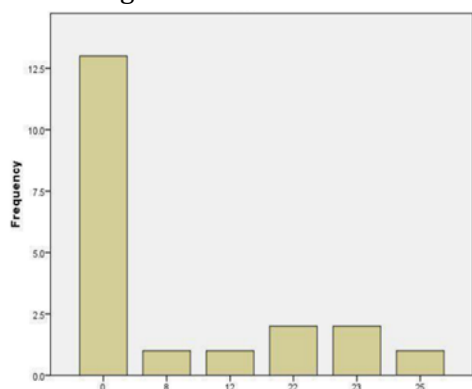


Figure 12: Frequency of smoking of the subjects

The average smoking is 6.75, the minimum is zero, and the maximum is 25 PY.

G) Satisfaction analysis of the people surveyed:

Satisfaction status of the subjects in the three states of dissatisfaction, complete satisfaction, and relative satisfaction is revealed in Figure 13.

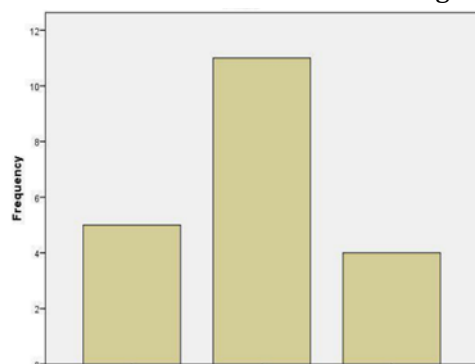


Figure 13: Frequency of satisfaction of the subjects

H) Analysis of the history of previous hypertrophic scars

The frequency of the history of hypertrophic scars in the subjects is presented in Figure 14.

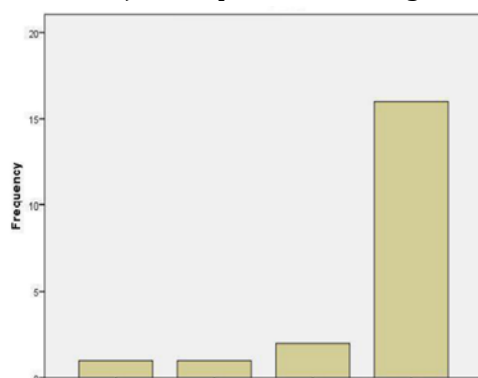


Figure 14: Frequency of hypertrophic scars in the subjects

Conclusions

Hypertrophic scarring and colloid after surgery, especially cosmetics, one of the most critical mastopexy surgery in women. It causes an inappropriate appearance and also significantly increases the cost of treatment. These costs include items that are paid to reduce and mask the scar, including expensive creams, lasers, tattoos, re-surgery, etc. These scars also cause psychological distress as well as complaints against doctors. Therefore, various methods have been proposed to reduce scars, one of which is Botox injections.

The 20 patients studied in this study underwent mastopexy surgery from March 96 to March 97 at Mehr Surgery Center and Rasoul Akram Hospital in Tehran, followed by scarring and colloid hypertrophy. Botox was injected into the right breast in each patient, and no injection was given into the left breast as a control. Patients were evaluated over 18 months. A significant difference was found between the group with Botox injection and without Botox injection in this study. Width, height, color, and flexibility scored significantly higher based on the Vancouver score. Also, the satisfaction of patients in the injection group was higher. There is a significant relationship between smoking and satisfaction in these patients, and we did not find a significant relationship between ages. This study is suggested to be examined in a larger sample of other surgeries in which the presence of scars is aesthetically essential, such as abdominoplasty, mammoplasty, groin lift, and other lifting procedures performed after massive weight loss, such as Brachioplasty. Also, use scales other than Vancouver in this study.

Funding

The current study was funded by Zahedan University of Medical Sciences.

Authors' contributions

All authors have contributed significantly and met criteria for authorship. All the authors read and approved the final copy of the manuscript.

Conflict of Interest

We have no conflicts of interest to disclose.

ORCID

Hamidreza Alizadeh Otaghvar:

<https://www.orcid.org/0000-0001-8535-3881>

Farnaz Amini:

<https://www.orcid.org/0000-0003-0928-3847>

Majid Pouya:

<https://www.orcid.org/0000-0003-4523-8867>

Saeid Pakseresht:

<https://www.orcid.org/0000-0002-2928-5076>

Maryam Milani Fard:

<https://www.orcid.org/0000-0002-0888-8847>

References

- [1]. Gassner H.G., Brissett A.E., Otley C.C., Boahene D.K., Boggust A.J., Weaver A.L., Sherris M.D., *Mayo Clin. Proc.*, 2006, **81**:1023 [Crossref], [Google Scholar], [Publisher]
- [2]. Young V.L., Hutchison J., *Plast. Reconstr. Surg.*, 2009, **124**:256 [Crossref], [Google Scholar], [Publisher]
- [3]. Atkinson J.A.M., McKenna K.T., Barnett A.G., McGrath D.J., Rudd M., *Plast. Reconstr. Surg.*, 2005, **116**:1648 [Crossref], [Google Scholar], [Publisher]
- [4]. Ghorbanizadeh S., Raziani Y., Amraei M., Heydarian M., 2021, **12**:54 [Crossref], [Google Scholar], [Publisher]
- [5]. Gauglitz G.G., Bureik D., Dombrowski Y., Pavicic T., Ruzicka T., Schaubert J., *Skin Pharmacol. Physiol.*, 2012, **25**:313 [Crossref], [Google Scholar], [Publisher]
- [6]. Babuccu B., Babuccu O., Yurdakan G., Ankarali H., *Ann. Plast. Surg.*, 2009, **63**:449 [Crossref], [Google Scholar], [Publisher]
- [7]. Al-Qattan M.M., Al-Shanawani B.N., Alshomer F., *Ann. Saudi. Med.*, 2013, **33**:482 [Crossref], [Google Scholar], [Publisher]
- [8]. Zimble M.S., Holds J.B., Kokoska M.S. Glaser D.A., Prendiville S., Hollenbeak C.S., *Arch. Facial. Plast. Surg.*, 2001, **3**:165 [Crossref], [Google Scholar], [Publisher]
- [9]. Lam S., *Facial Plast. Surg. Clin. N. Am.*, 2003, **11**:431 [Crossref], [Google Scholar], [Publisher]
- [10]. Verheyden J., Blitzer A., Other noncosmetic uses of BOTOX, *Dis. Mon.*, 2002, **48**:357 [Crossref], [Google Scholar], [Publisher]
- [11]. Berman B., Villa A.M., Ramirez C.C., Novel opportunities in the treatment and prevention of scarring, *J. Cutan. Med. Surg.*, 2004, **8**:32 [Crossref], [Google Scholar], [Publisher]
- [12]. Lee B.J., Jeong J.H., Wang S.G., Lee J.C., Goh E.K., Kim H.W., *Clin Exp Otorhinolaryngol*, 2009, **2**:20 [Crossref], [Google Scholar], [Publisher]
- [13]. Xiao Z., Qu G., *Molecules*, 2012, **17**:2169 [Crossref], [Google Scholar], [Publisher]
- [14]. Uyesugi B., Lippincott B., Dave S., *Am. J. Phys. Med. Rehabil.*, 2010, **89**:153 [Crossref], [Google Scholar], [Publisher]
- [15]. Babuccu B., Babuccu O., Yurdakan G., Ankarali H., *Ann. Plast. Surg.*, 2009, **63**:449 [Crossref], [Google Scholar], [Publisher]
- [16]. Goodman G.J., *J. Cutan. Aesthet. Surg.*, 2010, **3**:90 [Crossref], [Google Scholar], [Publisher]
- [17]. Feily A., Fallahi H., Zandian D., Kalantar H., *J. Cosmet. Dermatol.*, 2011, **10**:58 [Crossref], [Google Scholar], [Publisher]
- [18]. Gassner H.G., Sherris D.A., Friedman O., *Arch. Facial. Plast. Surg.*, 2009, **11**:140 [Crossref], [Google Scholar], [Publisher]
- [19]. Jablonka E.M., Sherris D.A., Gassner H.G., *Facial. Plast. Surg.*, 2012, **28**:525 [Crossref], [Google Scholar], [Publisher]
- [20]. Laskawi R., *Head Face Med.*, 2008, **10**:5 [Crossref], [Google Scholar], [Publisher]
- [21]. Tollefson T.T., Senders C.M., Sykes J.M., Byorth P.J., *Arch. Facial. Plast. Surg.*, 2006, **8**:221 [Crossref], [Google Scholar], [Publisher]
- [22]. Flynn T.C., *Dermatol. Surg.*, 2009, **35**:182 [Crossref], [Google Scholar], [Publisher]
- [23]. Shaarawy E., Hegazy R.A., Abdel Hay R.M., *J. Cosmet. Dermatol.*, 2015, **14**:161 [Crossref], [Google Scholar], [Publisher]
- [24]. Park T.H., Rah D.K., Chong Y., Kim J.K., *Ann. Plast. Surg.*, 2015, **74**:100 [Crossref], [Google Scholar], [Publisher]
- [25]. Robinson A.J., Khadim M.F., Khan K., *J. Plast. Reconstr. Aesthet. Surg.*, 2013, **66**:439 [Crossref], [Google Scholar], [Publisher]
- [26]. Chang C.S., Wallace C.G., Hsiao Y.C., Chang C.J., Chen, P.K., *Plast. Reconstr. Surg.*, 2014, **134**:511 [Crossref], [Google Scholar], [Publisher]
- [27]. Chang C.S., Wallace C.G., Hsiao Y.C., Chang C.J., Chen P.K., *PLoS One*, 2014, **9**:e115690 [Crossref], [Google Scholar], [Publisher]

- [28]. Wilson A.M., *Plast. Reconstr. Surg.*, 2006, **117**:1758 [[Crossref](#)], [[Google Scholar](#)], [[Publisher](#)]
- [29]. Raziani Y., Raziani S., 2021, 3:83 [[Crossref](#)], [[Google Scholar](#)], [[Publisher](#)]
- [30]. Ziade M., Domergue S., Batifol D., Jreige R., Sebbane M., Goudot P., Yachouh J., *J. Plast. Reconstr. Aesthet. Surg.*, 2013, **66**:209 [[Crossref](#)], [[Google Scholar](#)], [[Publisher](#)]
- [31]. Liu A., Moy R.L., Ozog D.M., *Dermatol. Surg.*, 2011, **37**:1740 [[Crossref](#)], [[Google Scholar](#)], [[Publisher](#)]
- [32]. Carruthers A., Kiene K., Carruthers J., *J. Am. Acad. Dermatol.*, 1996, **34**:788 [[Crossref](#)], [[Google Scholar](#)], [[Publisher](#)]
- [33]. Hallett M., *N. Engl. J. Med.*, 1999, **341**:118 [[Crossref](#)], [[Google Scholar](#)], [[Publisher](#)]
- [34]. Raziani Y., Othman BS., 2021, **10**: 5 [[Google Scholar](#)], [[Publisher](#)]
- [35]. Raziani Y., Othman BS., Raziani S., **69**, 102739 [[Crossref](#)], [[Google Scholar](#)], [[Publisher](#)]
- [36]. Ahmadi R., Ebadi A., Kalateh KH., Norouzi A., Amani V., 2008, **64**:m1407 [[Crossref](#)], [[Google Scholar](#)], [[Publisher](#)]
- [37]. Alizadeh R., Kalateh K., Khoshtarkib Z., Ahmadi R., Amani V., 2009, **65**: m1439 [[Crossref](#)], [[Google Scholar](#)], [[Publisher](#)]
- [38]. Kalateh KH., Ebadi A., Ahmadi R., Amani V., Khavasic HR., 2008, **64**:m1397 [[Crossref](#)], [[Google Scholar](#)], [[Publisher](#)]
- [39]. Ahmadi R., Kalateh K., Amani V., 2010, **66**:m512 [[Crossref](#)], [[Google Scholar](#)], [[Publisher](#)]
- [40]. Ahmadi R., Amani V., Khavasi HR., 2008, **64**:m1156 [[Crossref](#)], [[Google Scholar](#)], [[Publisher](#)]

HOW TO CITE THIS ARTICLE

Hamidreza Alizadeh Otaghvar, Farnaz Amini, Majid Pouya, Saeid Pakseresht, Mostafa Dahmardei, Sepehr Moghaddam, Aliakbar Jafarian, Maryam Milanifard. Medical and Pharmacological Evaluation of Scar Formation in Plastic Surgery, *J. Med. Chem. Sci.*, 2022, 5(4) 449-456
DOI: 10.26655/JMCHMSCI.2022.4.1
URL: http://www.jmchemsci.com/article_143142.html