



## Case Report Article

## The Effect of Low-Level Laser Therapy (LLLT) for Treatment of Bilateral Vocal Cord Paralysis Secondary to Lithium Battery Ingestion; a Case Report

Ali Akbar Jafarian<sup>1</sup>, Farnad Imani<sup>1</sup>, Zahra Jafarian<sup>2</sup>, Saied Amniati<sup>3</sup>, Mohaddesseh Jafarian<sup>4</sup>, Nooshafarin Kazemikhoo<sup>5</sup>, Hamidreza Alizadeh Otaghvar<sup>6,\*</sup>, Nastaran Khodakarim<sup>7</sup>, Sara Torabi<sup>8</sup>

<sup>1</sup>Pain Research Centre, Rasol Akram Hospital, Iran University of Medical Sciences, Tehran, Iran

<sup>2</sup>School of Dental medicine -Qom University of Medical Sciences, Tehran, Iran

<sup>3</sup>University of Medical Sciences - Hazrat-e Rasool General Hospital, Iran University of Medical Sciences, Tehran, Iran

<sup>4</sup>School of Medicine, Tarbiat Modaress University, Tehran, Iran

<sup>5</sup>Department of Dermatology, St. George Hospital, University of New South Wales, Sydney, Australia

<sup>6</sup>Department of Plastic Surgery, Iran University of Medical Sciences, Trauma Injury Research Centre of Iran University of Medical Sciences, Tehran, Iran

<sup>7</sup>Assistant Professor, Department of Medical Oncology and Hematology, Iran University of Medical Sciences, Tehran, Iran

<sup>8</sup>General Practitioner; Iran University of Medical Sciences, Tehran, Iran

## ARTICLE INFO

## Article history

Received: 2021-11-18

Received in revised: 2021-12-21

Accepted: 2021-12-24

Manuscript ID: JMCS-2111-1339

Checked for Plagiarism: Yes

Language Editor:

Ermia Aghaie

Editor who approved publication:

Professor Dr. Ehab AlShamaileh

DOI:10.26655/JMCS-2022.4.1

## KEYWORDS

LLLT

Bilateral vocal cord paralysis

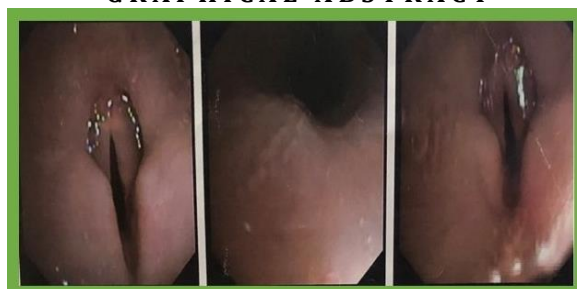Tracheostomy

Red light laser

## ABSTRACT

Bilateral vocal cord paralysis is one of the most dangerous electrochemical burns caused by lithium battery ingestion, especially in children. Current treatments usually include immediate battery removal to a range of conservative management techniques and invasive procedures, including tracheostomy, unilateral posterior cordotomy, thoracotomy, and other surgical procedures. This study reports a two-year-old girl with laryngeal electrochemical tissue burn and bilateral vocal cord paralysis due to lithium battery ingestion. She was treated by low-level laser therapy (LLLT) by TecmLP200, for Red Light Laser (650 nm) and Infrared Laser (810nm100 mw) on necks acupoint and some other points. The use of LLLT has been quite successful in treating the effects of ingestion of lithium battery on bilateral paralysis of the vocal cords. This therapeutic modality may be more effective, non-invasive, uncomplicated, tolerable, and affordable.

## GRAPHICAL ABSTRACT



\* Corresponding author: Hamidreza Alizadeh Otaghvar

✉ E-mail: Email: [drhralizade@yahoo.com](mailto:drhralizade@yahoo.com)

© 2022 by SPC (Sami Publishing Company)

## Introduction

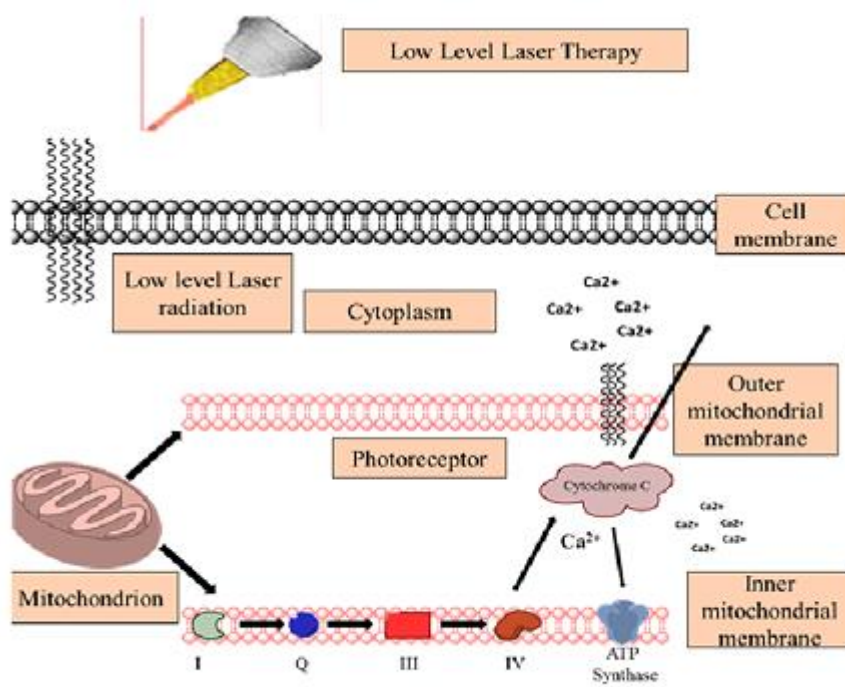
According to several reports, lithium battery ingestion, especially in children, causes several complications. The annual incidence rate is estimated at 10.5 per million, with a mortality rate of about 0.5%. Lithium battery ingestion mainly damages the esophageal mucosa. Injuries include pressure necrosis, electrochemical tissue burns, caustic exposure, or toxicity of heavy metals. Reported complications include severe esophageal ulcer, trachea-esophageal fistula or aorto-esophageal fistula, vocal fold pathology, and pneumonia. [1-3].

Tracheoesophageal fistulas (TEF) may be complicated by the high incidence of comorbidities such as recurrent laryngeal nerve injury, tracheal stenosis, recurrent fistula, or even mortality.

Studies of medical records of children with vocal cord paralysis and esophageal lithium battery ingestion have shown that it may cause serious

complications such as esophageal perforation, mediastinal infection, tracheal fistula, vocal cord paralysis, and life-threatening bleeding [4-6].

In a study, a 16-month-old boy with lithium battery ingestion developed bilateral voice paralysis due to misdiagnosis. This experiment shows that the initial detection of the presence of a lithium cell coin battery and its rapid removal may be the most effective intervention. Unusual upper respiratory distress in a young child should be a warning sign for physicians to perform X-rays of the chest and neck immediately. Another report suggests that aorto-esophageal fistula after button battery impaction may lead to upper gastrointestinal bleeding and cardiovascular collapse, which often tends to a fatal event (Figure 1) [2].



**Figure 1:** Effects and action mechanism of low-level laser therapy (LLLT): Applications in Periodontology

Various conservative or invasive approaches have been suggested to treat vocal cord paralysis in children due to lithium battery ingestion [27-30].

We reports a case of electrochemical tissue burn, bilateral vocal cord paralysis, and tracheal stricture following swallowing of button lithium battery who treated by low-level laser therapy

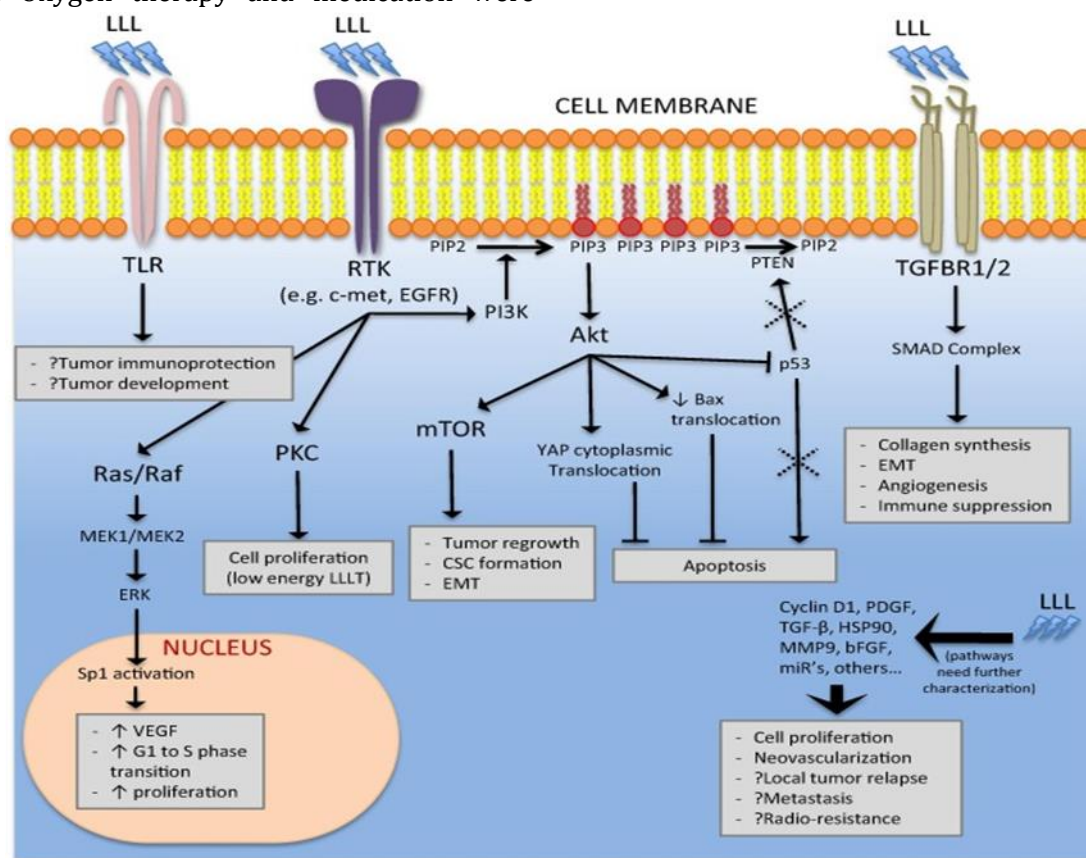
(LLLT) on necks local acupoint and some other effective points.

### Case presentation

A two-year-old girl with laryngeal electrochemical tissue burn and bilateral vocal cord paralysis due to lithium battery ingestion was admitted to the emergency department of

Pediatric Bahrami hospital of TUMS in October 2019 with severe respiratory symptoms, stridor, and cough. The anteroposterior (AP) and lateral radiographs showed a round, opaque object in the upper 1/3 area of the esophagus. Diagnostic bronchoscopy showed acute burns in the supraglottic region, upper trachea, and esophagus, along with laryngeal and pharyngeal edema. Under general anesthesia a 6-mm, 3-volt button lithium battery was removed about two hours after ingestion. After intubation, she was transferred to the Pediatric Intensive Care Unit (PICU). Oxygen therapy and medication were

started with antibiotics (IV cephalexin 30 mg/kg every 6 h), corticosteroids (hydrocortisone 50 mg twice daily), IV pantoprazole (10 mg twice daily), and sedatives. Because the patient had shortness of breath (SOB), tachypnea, and primary cyanosis, treatment with IV midazolam (0.1mg/kg), IV fentanyl (1 µg/kg), and atracurium (0.5 µg/kg) continued with mechanical ventilation. Over the next two days, ABG results showed that the respiratory acidosis had resolved, and extubation was performed on the third day (Figure 2).

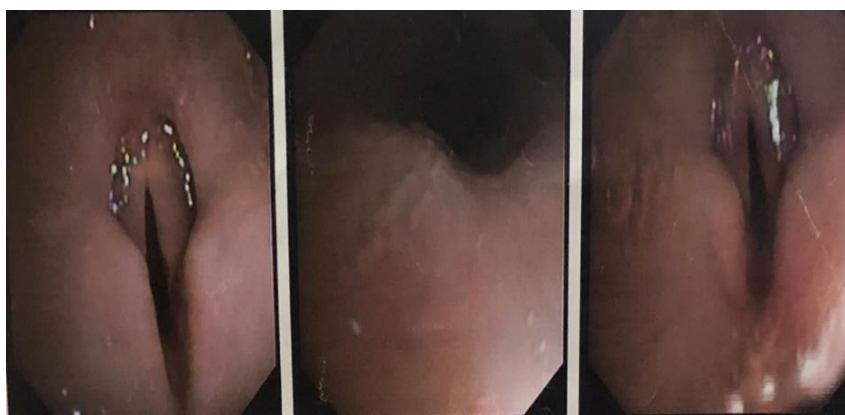


**Figure 2:** Could the biological robustness of low-level laser therapy (Photobiomodulation)

Since the patient developed upper and middle lobe atelectasis six hours after extubating, nasal intermittent positive pressure ventilation (NIPPV) was performed. During 32 days of hospitalization, she was being intubated twice due to shortness of breath (SOB), tachypnoea, cyanosis, and subsequently, respiratory acidosis. These events occurred again on the 12th, 13th, and 19th days of hospitalization. She was suffering from severe SOB attacks while eating

and crying during the day and 3-4 times during the night, which was treated with oxygen therapy.

Bronchoscopy on the 17th and 21st days also showed local lesions such as bilateral vocal cords paralysis, an ulcer of the posterior pharyngeal cavity (9x12 mm), fibrotic tissue at the subglottic region (1.5 cm), epiglottitis, subglottis, and oedema at the base of the tongue and soft palate (Figure 3).



**Figure 3:** Diagnostic bronchoscopy shows bilateral vocal cord paralysis

Upper GI series (UGI) on the 18th day of hospitalization showed interrupted peristalsis, micro-aspiration episodes while swallowing without oesophageal leakage, and she was a candidate for tracheostomy. Despite experts' for hospitalization, the patient was discharged with parental consent considering nasal intermittent positive pressure ventilation (NIPPV) and the use of a portable oxygen cylinder on the 32<sup>nd</sup> day.

The patient was hospitalized again overnight due to stridor, cyanosis, severe respiratory distress, so mechanical ventilation was performed. Tracheostomy was again recommended, which was rejected by the parents, and the child was discharged after 48 hours with parental consent. The same scenario repeated after 5 days, and she was hospitalized for 2 days. Fiberoptic bronchoscopy showed bilateral paralysis of the vocal cords without subglottic stenosis. For the third time, a tracheostomy was recommended, which was still rejected by the parents.

Finally, due to the potential risks and efficacy of LLLT in similar lesions, this therapeutic modality was recommended. The parents were also informed about the innovativeness and uncertainty of laser therapy's definitive effect on bilateral vocal cord paralysis. After accepting the use of this modality and even their insistence on doing LLLT, informed consent was obtained. Consequently, LLLT was performed with laser therapy based on the following therapeutic protocol. Alongside, nasal intermittent positive pressure ventilation (NIPPV) and a portable oxygen cylinder at home were recommended.

#### *Low-level laser therapy (LLLT) parameters*

LLLT was performed using TecmLP200, Iran Laser. Specifications for laser type included: Red

light laser (in the range of 650 nm), Infrared Laser (810 nm, 100 mw) with a fluence value of 1.5 J/Cm<sup>2</sup>. and spot size of 0.6 Cm<sup>2</sup>. It was implemented with a point size of 0.6 cm<sup>2</sup> and in a continuous wave (CW) mode at the necks acupoint as following the base of the tongue, paratracheal area, anatomical components of the larynx, including the anterior and lateral aspects of the cricoid cartilage and both recurrent laryngeal nerve (RLN) and 5 points including SP-6, ST-36, LI-11, DU-20, and LI-4. The treatment schedule was adjusted so that the patient underwent LLLT first 10 sessions daily and the subsequent 10 sessions on alternate days.

#### *Clinical Outcomes*

After 5 sessions of LLLT, SpO<sub>2</sub> (O<sub>2</sub> saturation) never decreased less than 90%, and the child had no severe SOB attack. After 10 sessions, the significant improvement in clinical outcomes was so apparent that it was reported to her physician at the hospital.

Considering the improvement of clinical and paraclinical parameters, the second course of treatment was scheduled for alternate days. At the end of the second course of LLLT, the SpO<sub>2</sub> range rose to 97-99%. The LLLT procedure was stopped for a week while the parents regularly reported the patient's clinical status. Subsequently, the relevant laser therapist examined the patient, and the Pso<sub>2</sub> range was increased to 99-98%. She just complained about her mild respiratory stridor after exertion or severe crying. The patient showed no -exertional SOB, no respiratory stridor, and since SpO<sub>2</sub> had reached an acceptable level, oxygen therapy ceased.



During the 3, 6, and 10-month follow-up periods, her clinical and paraclinical parameters were consistent in fortnightly reviews. Bronchoscopic examination also revealed normal vocal cord movement without any abnormalities in her tongue base, tongue base, pyriform sinus, subglottic region, and trachea. Follow-up using bronchoscopy for one year did not demonstrate any respiratory or speech disorders and hence did not require further treatment.

### Discussion

Vocal cord paralysis (VCP) is a relatively common lesion usually caused by trauma, tumour, chemical ingestion, cervical region surgery, prolonged intubation, and affects the vagus nerve or its recurrent laryngeal nerve branch [15,16]. The main symptoms include shortness of breath (SOB), hoarseness, shortness of breath, and difficulty swallowing. [17,18]. Usually, in bilateral paralysis of the vocal cords, the patient does not recover within 6 weeks and may need a tracheostomy or other surgery. Such treatments are often complex for parents to accept because of their side effects. [19].

Several RCTs reveal the effectiveness of LLLT in decreasing inflammation, tissue regeneration, and wound healing, especially in diabetic wounds and burn wounds [20-22]. Another RCT suggests using 810 nm IR light to accelerate functional recovery regarding the effects of this treatment on nerve injury after surgery [23].

Few studies have been conducted to evaluate the effectiveness of laser therapy in cases of vocal cord paralysis or other oropharyngeal pathologies. The other RCT reported that red laser light might normalize voice fatigue. They performed radiographic tests using an IR-sensitive camera for infrared light and a rigid endoscope for red light to confirm adequate light penetration from the ventral neck surface through the laryngeal mucosa, vocal cords, and paraglottic space. They showed that approximately 1.5% of red light and 8.4% of infrared light reach the skin's medial vocal fold surface (Kagan). A randomized clinical trial showed that IR laser reduces neutrophil influx and improves laryngeal reparative collagen synthesis [25].

Biswas *et al.* (2010) presented a case in which the closure of a large tracheoesophageal fistula was achieved with conservative management planning. They discovered that most of these cases occur in children and are routinely controlled with surgical repair. Non-intervention management should first be tried to manage tracheoesophageal fistulas acquired in children [26]. Gopal *et al.* (2015) reported a case in which a three-year-old child developed a large tracheoesophageal fistula for 36 h due to the placement of a button battery. Surgical access was obtained through right cervical incision and median sternotomy. Fistula repair required segmental resection of both the trachea and esophagus followed by primary anastomosis [19]. Bekhof *et al.* (2005) reported four children were admitted due to button battery ingestion. In two cases, an uncomplicated period and spontaneous passage of batteries occurred [20]. The other two patients (an 11-month-old girl and a 6-week-old girl) developed severe complications. In one of them, esophageal stenosis, and another, a significant clinical course with tracheoesophageal fistula and esophageal injury occurred. If the battery is located in the esophagus, it should be removed immediately by endoscopy [1]. They take a conservative approach when the battery is placed in the stomach or beyond and there is no particular complaint [7].

Leinwand *et al.* (2005) investigated a therapeutic modality to manage button battery ingestion in children. They consider tracking patient care after battery consumption to be necessary for evaluating medium-term complications (e.g., bleeding) and long-term complications (i.e., the formation of stenosis). In most cases of significant esophageal injury (especially circumferential injury), repeating the esophagram at 4 weeks after battery removal is a prudent measure to assess esophageal stricture. If patients' clinical conditions are normal and asymptomatic, no additional monitoring is needed unless nutritional problems occur. In the case of esophageal stricture, endoscopic dilation should be considered immediately, as 4 weeks should be sufficient for a recovery period to minimize the risk of perforation. Respiratory

status assessment should also be performed for tracheal erosion/injury [ʳ].

Richter *et al.* (2008) examined acquired tracheoesophageal fistula (TEF) following disc-battery ingestion. The late recurrence of TEF following conservative management and endoscopic and radiographic evidence of closure indicates the importance of long-term evaluations before fistula recovery is assumed. Risks and benefits should be weighed against conservative approaches to TEF management before selecting surgical-based approaches. If conservative management practices are used, long-term follow-up (at least 6 months) should begin with a high degree of suspicion. According to this study, tracheal repair using imbricated suture technique can be a suitable surgical option if such an approach fails [ʒ].

Anand *et al.* (2002) presented a rare case of spontaneous closure of a secondary oesophageal tracheal fistula to disk battery ingestion. They also proposed conservative management, which led to its closure on its own [ʝ].

Duan *et al.* (2021) suggested that primary medications through neurotrophic drugs and glucocorticoids may help improve the movement of the vocal cords following lithium-ion battery ingestion in children to avoid tracheotomy [ʋ].

Simonin *et al.* (2013) also reported a 16-month-old case with bilateral voice paralysis who underwent unilateral posterior cordotomy after lithium battery ingestion, and the patient was successfully extubated [26].

Hosokawa *et al.* (2021) have proposed a combination of cervical incision with a median sternotomy as a method for safe resection and anastomosis in cases with a large fistula and wider tracheal and esophageal involvement [27].

### Conclusions

Compared to conventional therapies, it seems that the mentioned modality may be completely non-invasive, effective, uncomplicated, tolerable, and affordable, especially in children. However, more clinical and paraclinical studies with higher sample sizes are needed for its development. Reviewing past studies, our case investigation maybe is the first report of using LLLT for non-invasive treatment of bilateral vocal cord

paralysis to prevent tracheostomy and showed the effectiveness on acupoint of the neck and other effective points. This therapeutic modality was also successful in healing laryngeal ulcers, reducing local edema, and nerve regeneration. However, more clinical investigations with a higher sample size are required.

### Funding

This research did not receive any specific grant from funding agencies in the public, commercial, or not-for-profit sectors.

### Authors' contributions

All authors contributed toward data analysis, drafting and revising the paper and agreed to be responsible for all the aspects of this work.

### Conflict of Interest

We have no conflicts of interest to disclose.

### ORCID

Hamidreza Alizadeh Otaghvar:

<https://www.orcid.org/0000-0001-8535-3881>

### References

- [1]. Anand T.S., Kumar S., Wadhwa V., Dhawan R., *Int. J. Pediatr. Otorhinolaryngeal.*, 2002, **63**:57 [[Crossref](#)], [[Google Scholar](#)], [[Publisher](#)]
- [2]. Biswas D., Majumdar S., Ray J., Bull P., *J. Laryngol. Otol.*, 2010, **124**:1136 [[Crossref](#)], [[Google Scholar](#)], [[Publisher](#)]
- [3]. Duan Q., Zhang F., Wang G., Wang H., Li H., Zhao J., Zhang J., Ni X., *Eur. J. Pediatr.*, 2021, **180**:1059 [[Crossref](#)], [[Google Scholar](#)], [[Publisher](#)]
- [4]. Gopal M., Westgarth-Taylor C., Loveland J., *Afr. J. Paediatr. Surg.*, 2015, **12**:91 [[Crossref](#)], [[Google Scholar](#)], [[Publisher](#)]
- [5]. Goussard P., Morrison J., Neld E., Mfingwana L., Andronikou S., Blokland R.A., Mukhtar A., Looock J.W., de Bruyn G.H.M., *Pediatr. Pulmonol.*, 2021, **56**:2366 [[Crossref](#)], [[Google Scholar](#)], [[Publisher](#)]
- [6]. Grisel J.J., Richter G.T., Casper K.A., Thompson D.M., *Int. J. Pediatr. Otorhinolaryngol.*, 2008, **72**:699 [[Crossref](#)], [[Google Scholar](#)], [[Publisher](#)]

- [7]. Hofmeyr R., Bester K., Willms A., Hewitson J., Byhahn C., *Anaesthetist*, 2019, **68**:777 [[Crossref](#)], [[Google Scholar](#)], [[Publisher](#)]
- [8]. Karu T., *Photomed. Laser Surg.*, 2013, **31**:189 [[Crossref](#)], [[Google Scholar](#)], [[Publisher](#)]
- [9]. Kazemi-Khoo N., *foot.*, 2006, **16**:184 [[Crossref](#)], [[Google Scholar](#)], [[Publisher](#)]
- [10]. Kazemikhoo N., Sarafnejad A.F., Ansari F., Mehdipour P., *J. Lasers Med. Sci.*, 2016, **31**:1537 [[Crossref](#)], [[Google Scholar](#)], [[Publisher](#)]
- [11]. Leinwand K., Brumbaugh D.E., Kramer R.E., *Gastrointest Endosc Clin. N. Am.*, 2016, **26**:99 [[Crossref](#)], [[Google Scholar](#)], [[Publisher](#)]
- [12]. Takano S., Nito T., Tamaruya N., Kimura M., Tayama N., *Auris Nasus Larynx*, 2012, **39**:597 [[Crossref](#)], [[Google Scholar](#)], [[Publisher](#)]
- [13]. Gupta J., Varshney S., Bist S., Bhagat S., *Indian Otolaryngol. Head Neck Surg.*, 2013, **65**:16 [[Crossref](#)], [[Google Scholar](#)], [[Publisher](#)]
- [14]. Erovic B.M., Shah M.D., Bruch G., Johnston M., Kim J., O'Sullivan B., Perez-Ordóñez B., Weinreb I., Atenafu E.G., de Almeida J.R., Gullane P.J., *Otolaryngol. Head Neck Surg.*, 2015, **44**:43 [[Crossref](#)], [[Google Scholar](#)], [[Publisher](#)]
- [15]. Pinto J.A., Godoy L.B., Marquis V.W.P.B., Sonego T.B., Leal C.D.F.A., *Braz. J. Otorhinolaryngol.*, 2011, **77**:594 [[Crossref](#)], [[Google Scholar](#)], [[Publisher](#)]
- [16]. Martínez-Balzano C.D., Greenberg B., *Chest*, 2014, **146**:e153 [[Crossref](#)], [[Google Scholar](#)], [[Publisher](#)]
- [17]. Dahmardehei M., Kazemikhoo N., Vaghardoost R., Mokmeli S., Momeni M., Nilforoushzadeh M.A., Ansari F., Amirkhani A., *Lasers Med. Sci.*, 2016, **31**:497 [[Crossref](#)], [[Google Scholar](#)], [[Publisher](#)]
- [18]. Kazemikhoo N., Vaghardoost R., Dahmardehei M., Mokmeli S., Momeni M., Nilforoushzadeh M.A., Ansari F., Razagi M.R., Razagi Z., Amirkhani M.A., Masjedi M.R., *J. Lasers Med. Sci.*, 2018, **9**:139 [[Crossref](#)], [[Google Scholar](#)], [[Publisher](#)]
- [19]. Vaghardoost R., Momeni M., Kazemikhoo N., Mokmeli S., Dahmardehei M., Ansari F., Nilforoushzadeh M.A., Abadi S.M., Gharagheshlagh S.N., Sassani S., *Lasers Med. Sci.*, 2018, **33**:603 [[Crossref](#)], [[Google Scholar](#)], [[Publisher](#)]
- [20]. Moges H., Wu X., McCoy J., Vasconcelos O.M., Bryant H., Grunberg N.E., Anders J.J., *Lasers Surg. Med.*, 2011, **43**:901 [[Crossref](#)], [[Google Scholar](#)], [[Publisher](#)]
- [21]. Kagan L.S., Heaton J.T., *J. Voice*, 2017, **31**:384.e15 [[Crossref](#)], [[Google Scholar](#)], [[Publisher](#)]
- [22]. Marinho R.R., Matos R.M., Santos J.S., Ribeiro M.A., Ribeiro R.A., Lima R.C., Albuquerque R.L., Thomazzi S.M., *Lasers Med. Sci.*, 2014, **29**:239 [[Crossref](#)], [[Google Scholar](#)], [[Publisher](#)]
- [23]. Simonin M., D'Agostino I., Lebreton M., Jughon O., Hamza J., Oualha M., *Eur. J. Pediatr.*, 2013, **172**:991 [[Crossref](#)], [[Google Scholar](#)], [[Publisher](#)]
- [24]. Ruhl D.S., Cable B.B., Rieth K.K., *Ann. Otol. Rhinol. Laryngol.*, 2014, **123**:206 [[Crossref](#)], [[Google Scholar](#)], [[Publisher](#)]
- [25]. Jahandideh H., Yarahmadi A., Rajaieh S., Ostvar Shirazi A., Fard M.M., Yarahmadi A., *JPRI*, 2019, **1** [[Crossref](#)], [[Google Scholar](#)], [[Publisher](#)]
- [26]. Etemadi S., Mahmoodiyeh B., Rajabi S., Kamali A., Milanifard M., *Ann. Romanian Soc. Cell Biol.*, 2021, **25**:2417 [[Google Scholar](#)], [[Publisher](#)]
- [27]. Fard A.M.M., Fard M.M., *Eurasian J. Sci. Tech.*, 2021, **1**:284 [[Crossref](#)], [[Google Scholar](#)], [[Publisher](#)]

#### HOW TO CITE THIS ARTICLE

Ali Akbar Jafarian, Farnad Imani, Zahra Jafarian, Saied Amniati, Mohaddeseh Jafarian, Nooshafarin Kazemikhoo, Hamidreza Alizadeh Otaghvar, Nastaran Khodakarim, Sara Torabi. The Effect of Low-Level Laser Therapy (LLL) for Treatment of Bilateral Vocal Cord Paralysis Secondary to Lithium Battery Ingestion; A Case Report, *J. Med. Chem. Sci.*, 2022, 5(4) 406-412

DOI: 10.26655/JMCHMSCI.2022.4.1

URL: [http://www.jmchemsci.com/article\\_142451.html](http://www.jmchemsci.com/article_142451.html)